

**PRACTICAL MANUAL
OF
VETERINARY ANATOMY**

(B.V.Sc. & A.H. FIRST PROFESSIONAL YEAR 2023-24)

Volume III (Unit- VII & VIII)



DEPARTMENT OF VETERINARY ANATOMY & HISTOLOGY
MJF COLLEGE OF VETERINARY & ANIMAL SCIENCES,
CHOMU, JAIPUR (RAJASTHAN)

**PRACTICAL MANUAL
IN
VETERINARY ANATOMY**

NAME:
ROLL NO. :
BATCH:

(B.V.Sc. & A.H. FIRST PROFESSIONAL YEAR 2023-24)

**DEPARTMENT OF VETERINARY ANATOMY & HISTOLOGY
MJF COLLEGE OF VETERINARY & ANIMAL SCIENCES,
CHOMU, JAIPUR (RAJASTHAN)**

CERTIFICATE

This is to be certify that Mr. /Ms.
..... Roll. No.....of First year B.V.Sc &
A.H. has successfully completed all practicals in Veterinary Anatomy during first
year of the academic year

Date :

Place :

Signature of Head of Department

Signature of Course Teacher

FOREWORD

I am very happy to go through the Practical Manual entitled “Veterinary Anatomy” Department of Veterinary Anatomy & Histology, MJF College of Veterinary & Animal Sciences, Chomu, Jaipur (RAJ.) The Manual covers the practical syllabus of undergraduate course (Veterinary Anatomy, Volume - III) prescribed by Veterinary Council of India (MSVE 2016) for B.V.Sc & A.H. programme.

The Manual is a good attempt and is based on cumulative experience of teaching undergraduate courses. The language used in the manual is simple and lucid. The outline and description of practical exercises covering objectives, materials required, procedures and observations to be taken have been nicely presented which would be helpful in conducting practicals more effectively.

I hope this manual will make its own place in the libraries of Veterinary and Animal Science Colleges/Universities and various Livestock Institutions in near future.

I congratulate the authors for the efforts put in bringing out this practical manual.

Dean

MJF College of Veterinary &
Animal sciences, Chomu, Jaipur

ACKNOWLEDGEMENT

Ever since the introduction of new course for professional B. V. Sc. & A.H. degree programme under Veterinary Council of India pattern in Veterinary Colleges/Universities in the country, there was a dire need to have a practical manual on Veterinary Anatomy subject which covers the practical syllabus of undergraduate (Veterinary Anatomy). This new course was not independently developed in most of the Veterinary College/University before the introduction of Veterinary Council of India programme (MSVE 2016). The present manual covers the practical with objectives, material required, procedure, steps to follow, precautions to be taken, observations to be recorded and exercise to be done by the students. We hope that users will find the manual immensely useful.

We look forward to receiving the valuable suggestions of users for improvement of this manual

Name & Roll No. of the student: _____

INDEX

S.No.	Title	Page No.	Date	Signature
1				
2				
3				
4				
5				
6				
7				
8				
9				
10				

Practical No. 1

MICROSCOPY AND MICROMETRY

1. Foot
2. Arm
3. Body tube
4. Coarse adjustment knob
5. Fine adjustment knob
6. Stage
7. Condenser with iris diaphragm
8. Mirror/illuminator
9. Lenses:

Ocular lens	5x, 10x, 15x, 20x
Objective lens	4x, 10x, 40/45x, 100x
Condenser lens	only for adjustment of light

10. Magnification:

Light microscope	Max ^m 1000x, 2000x (ocular x objective)
Electron microscope	5000x to 20000x.

11. Resolving power:

Resolving power of a lens is its capacity to give clear images of points close together.

$$R = 0.61\lambda/NA$$

Where R = Resolution power (μm), λ = Wave length of light (μm)

NA = Numerical aperture

In most student microscopes λ is 5400\AA , NA is 1.25 so R is $0.28\mu\text{m}$

In electron microscope R is 20\AA to 10\AA ($0.001\mu\text{m}$)

12. Working distance :

Low power	7.0mm
High power	0.6mm
Oil immersion	0.13mm

13. Types of microscopy:

Bright field microscopy, UV microscopy, fluorescence microscopy, dark field microscopy, phase contrast microscopy, interference microscopy, polarizing microscopy, transmission electron microscopy, scanning electron microscopy.

14. Measurements:

Unit	Symbol and relation
Micron	$= 1\mu = 0.001\text{mm} = 10000\text{\AA}$
Millimicron	$= 1\text{m}\mu = 0.001\mu = 10\text{\AA}$
Angstrom	$= 1\text{\AA} = 0.1\text{m}\mu = 0.0001\mu$ $= 1\text{\AA} = 1 \times 10^{-7} \text{mm}$

Q1: Draw a labeled diagram of light microscope?

Q2: Write down difference between light and electron microscopy?

Practical No. 2

HISTOLOGICAL TECHNIQUES

HISTOLOGICAL PROCESSING:

1. Collection of tissue:

The tissue should be collected from the animal as soon as possible after death without mauling it and placed in suitable fixative. The size of the tissue should not be more than 5mm thick and ratio of tissue and fixative should be 1:20.

2. Fixation:

Fixation of tissue is done to achieve following objectives:

- a) To prevent the tissue from putrefactive and autolytic changes.
- b) To protect the tissue by hardening the soft tissue.
- c) To convert the semi fluid consistency of cell into semisolid consistency.
- d) To aid in visual differentiation of structure.

Commonly used fixatives are buffered neutral 10% formaline, Zenker's fixative, Bouin's solution etc. some organic tissues are infiltrated with calcium salts (calcified). These salts provide hardness and rigidity to bone/tissue and must be removed to assure that the specimen is soft enough to allow cutting. Such specimen is placed in large quantity of any (of following) decalcifying fluid e.g. Perenyl's fluid, formic acid-sodium citrate fluid etc.

3. Trimming of tissue:

The tissues are trimmed to appropriate size by putting the tissue on wax block.

4. Washing:

Overnight or 18 hours with fresh running tap water.

5. Dehydration:

By passing tissue (may be kept in tissue capsules) through series of alcohol of increasing concentrations i.e. 70, 80, 90, 95 and 100 percent alcohol. Water is removed from the tissue. Other dehydrates are acetone, butanol, dioxane etc. The later are clearing agents too.

6. Clearing:

The opacity of the tissue is removed by placing the tissue into the clearing agents (volatile/oil substance) such as xylene, benzene, cedar-wood oil etc. which is miscible with both 100% alcohol and paraffin. Now tissues become translucent. This step is essential before infiltrating the dehydrated tissue with paraffin because alcohol and paraffin don't mix.

7. Infiltration:

Melted paraffin replaces clearing agent completely during infiltration. This is done at a temperature just above the melting point (58-60°C) of the paraffin mixture by at least 3 changes of paraffin bath.

8. Embedding:

When infiltration is complete the specimen is transferred to an embedding mold/'L' mold of melted paraffin, which is allowed to harden. Glycerin should be applied in mold before putting melted paraffin in it.

9. Trimming:

The mold is removed after hardening of paraffin and excess paraffin is trimmed away from the paraffin block.

10. Sectioning of paraffin block: (MICROTOMY)

The block of paraffin is secured to the microtome and oriented appropriately with respect to the knife. With each revolution of the microtome handle, the specimen moves through the blade and a section of desired thickness is produced. Each successive section adheres to the preceding one, forming a continuous ribbon. Subsequently one or more sections are carefully separated from the ribbon and transferred to the surface of the warm (58°C) water in a water bath. This softens the paraffin and flattens the section, eliminating wrinkles. The flattened sections are floated onto a slide, which is then placed on a slide warming table. As the preparation dries, the section adheres to the surface of the slide. For adhering the section to the surface of the slide egg albumen may be used. Egg albumen is applied on the surface of a slide using a sponge and then dried. These albumenized glass slides are used for picking up the floating sections from water bath.

11. Staining:

- i) Deparaffinization of section with xylene and the specimen is rehydrated.
- ii) Rehydration of the section is done by passing the section through series of alcohol of decreasing concentration i.e. 100%, 95%, 90%, 70%, 50% and then finally water.
- iii) Staining (the sections are stained and counter stained by using nuclear & cytoplasmic stains).
- iv) Dehydration of the section is done by passing section through the series of alcohol of increasing concentrations to 100% alcohol.
- v) Clearing the section. The sections are cleared (made transparent) with xylene.
- vi) Mounting the section – stain sections are covered by the resins (Gum dammar, Canada balsam (natural) DPX (synthetic) and a cover slip (no. 01-1.0) is placed over it.

Practical No. 3

CELL STRUCTURE AND DIVISION

Cell is the structural and functional unit of living material of a multicellular organism. Surrounded by the cell membrane, the cell is composed of a membrane bounded nucleus and cytoplasm that contains organelles and inclusions.

Cytoplasmic organelles are the permanent structures lying in the cytoplasmic matrix. Where particular organization gives them a specific function in the metabolism of the cell.

1. Cell membrane.
2. Endoplasmic reticulum
 - Rough endoplasmic reticulum having ribosomes.
 - Smooth endoplasmic reticulum
3. Annulate lamellae, centrioles and basal bodies.
4. Golgi apparatus
5. Lysosomes
6. Peroxisomes
7. Cytoskeleton
 - Microfilaments
 - Myosin
 - Intermediate filaments
 - Microtubules

Cytoplasmic inclusions:

1. Secretory inclusions

Zymogen
Mucoid material
Serous material

2. Nutritive inclusions

Glycogen
Lipid

3. Miscellaneous inclusions

Melanin
Lipofuscin
Hemosiderin
Crystalline inclusions

Various types of cells – cell shape-

Flat, cubical, columnar, polyhedral, Pyramidal, spherical, elongated.

Various types of nuclei –

Oval, spherical, elongated, lobulated, multilobular.

Chromatic mass-

Distribution- Heterochromatic, Euchromatic

Staining – Vesicular, hyper chromic, hypochromic.

EXERCISE:

1. Draw and labeled the diagram of animal cell.
2. Draw and labeled the diagram of mitosis and meiosis.

Practical No. 4

EPITHELIUM

The surface of the body and lining of the tubes or passages and the surface of the various cavities in the body are lined by cells which are closely approximated to each other and have a minimal amount of intercellular substance. This lining cellular layer is called epithelium. Epithelium is separated from the underlying connective tissue by a thin membrane known as basement membrane. It is composed of two layers, the basal lamina and the reticular lamina.

Classification:

The basis of classification:

Shape of the epithelial cells- Squamous, Cuboidal, and Columnar.
Number of layers present- Simple and Compound.

1. Simple epithelium

Simple epithelium is a single layer of epithelial cells resting on a basement membrane.

Characteristics:

a) Simple squamous epithelium:

It consists of single layer of thin, flat, scale like cells. A spherical or ovoid nucleus is present near the centre of the cell causing a bulging in that area.

Examples:

Endothelium: in the heart, blood and lymph vessels having continuous or discontinuous layer of flat cells.

Mesothelium: lining the peritoneal, pleural and pericardial cavities.

Mesenchymal epithelium: in the subarachnoid and subdural spaces anterior chamber of eye, perilymphatic spaces of the internal ear.

b) Simple cuboidal epithelium:

It is a single layer of cells whose height and width are approximately equal.

Examples:

Non-ciliated cuboidal epithelium: in ducts of glands, choroids, plexus, ciliary body. Pyramidal.

Glandular epithelium: in acini ciliated cuboidal epithelium in uterus of mouse.

c) Simple columnar epithelium: It consists of all narrow cells with considerably greater height than width. Nucleus is oval and located near the base of the cell. Generally this epithelium lines the organs with absorptive function and has striated border.

Examples:

Small and large intestines, vesicular gland. Glandular epithelium of glands, Goblet Cell is its modification.

Ciliated columnar epithelium: in oviduct, epididymis.

Non-ciliated columnar epithelium: in kidney gall bladder.

d) Pseudo stratified ciliated columnar epithelium:

It is composed of single layer of cells, the cells are irregular in shape and size, and their nuclei are located at various levels giving it a stratified appearance. All the cells reach basement membrane but not the free surface. Those cells that reach the surface are ciliated/non-ciliated epithelial cells, goblet cells. The basal cells are attached to the basal lamina but do not reach surface. The ciliated cells have two types of cilia, non-motile stereocilia and motile kinocilia.

Examples:

Trachea, primary bronchioles.

2. STRATIFIED EPITHELIUM:

It consists of two or more layers of cells. It is convention to name its different types on the basis of form of the surface cells.

Characteristics:

a) **Stratified squamous epithelium:** It has 8-12 layers, up to 50 or more can be found.

Basal cells = small cuboidal/columnar, Intermediate cells = polygonal, and Superficial cells = flat.

Examples:

Keratinized non-nucleated = skin epidermis. In herbivores-mouth, pharynx, oesophagus.

Non-Keratinized = in carnivore- mouth, pharynx, oesophagus, cornea, vagina, glans penis, part of urethra.

b) Stratified cuboidal epithelium: Cuboidal cells are present in the top layer found at the junction of stratified and pseudo-stratified/transitional epithelium. Examples: Graafian follicle of ovary, conjunctiva ducts of sweat and sebaceous glands.

c) Stratified columnar epithelium: Columnar cells are present in the top layer and polygonal cells are present in the deep layer. Examples: Oropharynx, nasopharynx, excretory ducts of large glands such as mammary gland, cavernous portion of male urethra.

d) Transitional epithelium: Found where frequent stretching and contraction occurs.

In contracted state – 5-7 layers of cell, Basal cells – cuboidal to columnar, Intermediate – elongate, polyhedral, Surface cells – cuboidal/pear/ballon/pillow shaped cells.

In distended state: 2-3 layers, Superficial cells flat as in stratified squamous epithelium.

Examples:

Urinary system – pelvis of kidney, ureter, urinary bladder, portion of urethra.

3. MODIFIED EPITHELIUM:

Cells structure modified according to function.

a) **Ciliated epithelium:** Cuboidal/columnar cells on the free surface bear cilia.

(i) **Motile/true/kinocilia** – pseudo-stratified columnar epithelium of respiratory and female reproductive tract.

(ii) **Non-motile/stereocilia** (form brush border of PCT and striated boarder in small intestine, have no basal bodies) – PCT (Proximal convoluted tubules) of kidneys. In epididymis- long steriocilia (absorptive & secretory function).

b) Glandular epithelium:

(i) Mucous cells – large, secretory droplet at apex – e.g. goblet cells.

(ii) Serous cells – small, secretory granules at apex, basophilic cytoplasm – parotid salivary gland, pancreas, lacrimal gland.

(iii) Seromucous cells - Serous part form (cap or half moon shape (Demilune), over main acini mucous part. e.g. Mandibular and sublingual salivary glands.

c) Neuro-epithelium: The cells have modified to carry sensory function for reception of external stimuli. Usually tall columnar cells with non-motile hair like processes – hair cells, sensory cells, e.g. taste buds of tongue, olfactory cells, organ of corti, rods and cones of retina.

d) Myoepithelium: Epithelial cells when modified into spindle shaped structure like muscle cells with contractile nature of its branching processes – called myoepithelial cells. e.g. present around alveoli of mammary gland, sweat glands.

e) Pigmented epithelium: Pigment granules are present in the cells.

e.g. stratum germinativum of skin, external epithelium of retina, ciliary body of eye, iris.

Special epithelial structures: Border modification of epithelial cells as per requirements of the cells in that particular location. Modifications in epithelial cells and their borders include:

a) Cytoplasmic modifications:

Tonofibrils (fine fibrils) in stratified squamous epithelium (Prickle cells) of skin. They may extend into subepithelial tissue from the basal cells of the skin.

b) Free border modifications: Microvilli – They are cytoplasmic extensions to increase the surface area for absorption/secretion. They may form cilia (two types) and brush border.

c) Lateral border modifications:

Desmosomes – thickening of cell membrane due to convergence of tonofibrils found in thick stratified squamous epithelium such as skin. (Prickle cells).

Intercellular bridges – fine processes connecting adjacent cells formed by desmosomes of adjacent cells. (Prickle cells).

Intercellular cement – adhesive substance between cells, which hold them together.

Terminal bars – thickening of cementing substance between terminal portions of cuboidal/ columnar epithelium.

Intercellular canaliculi – fine tubules extending from lateral surfaces or basal surface into cytoplasm of the cell. E.g. cells of many glands.

d) Basal border modifications:

Hemidesmosomes – thick material deposition.

Podocytes – in glomerular epithelium visceral layer of Bowman’s capsule contain podocytes, which have foot like process extending from their basal border.

Intercellular canaliculi – fine tubules extending from lateral surfaces or basal surface into cytoplasm of the cell e.g. cells of many glands.

GLANDS

Epithelial cells are modified into secretory structures or glands. Glands are classified.

1. On the basis of morphologic characteristics:

a) **Unicellular** e.g. Goblet cells.

b) **Multicellular** e.g. Salivary gland

2. On the basis of type of secretory product:

a) **Serous** e.g. Lacrimal and Parotid gland.

b) **Mucous** e.g. Sublingual and Bulbourethral gland.

c) **Mixed** e.g. Mandibular salivary gland.

3. On the basis of mode of secretions:

a) **Merocrine** e.g. Salivary glands.

b) **Apocrine** e.g. Sweat glands.

c) **Holocrine** e.g. Sebaceous glands.

d) **Cytocrine** e.g. Testes.

1. On the basis of morphologic characteristics:

a) **Unicellular:** Single secretory cell in a non-secretory epithelium e.g. Goblet cells.

b) **Multicellular:** Composed of more than one cells

i) **Intraepithelial glands** are clusters of a few secretory cells within the surface epithelium. e.g in vasa efferentia and vas deferens of ox.

ii) **Extraepithelial glands** are large accumulation of cells that have proliferated into underlying connective tissue. e.g. gastric and intestinal glands.

iii) **Endocrine glands** are those multicellular glands which do not have a system of ducts to convey their secretory product to the site of utilization; instead it is released directly into the intercellular fluid from which it is transported to the site of action by the blood and lymph.

iv) **Exocrine glands** are those multicellular glands which have a system of ducts to transport their secretory product to the site of utilization. These are further classified into following types.

Simple glands: Having single or several secretory units connected to the surface through an unbranched duct.

a) **Simple tubular:**

Simple straight tubular

In large intestine (straight terminal portion)

Simple coiled tubular

Sweat glands of skin (coiled terminal portion)

Simple branched tubular	Stomach glands (branched terminal portion)
b) Simple acinar or alveolar:	
Simple acinar	Some rare sebaceous glands in skin of amphibians. Enlarged spherical unit connected to the surface by a constricted portion.
Simple branched acinar	Large sebaceous glands of the skin. Two or more acini or alveoli occur together and their secretion pour through a common opening.
c) Tubulo-alveolar (tubulo-acinar):	
Simple tubulo-alveolar	Minor salivary glands in oral cavity. These are composed of both a tubular portion and an enlarged terminal acinus. Have three types of secretory units. (i) Tubular (ii) Acinar(iii) Tubulo-acinar

Compound glands- These are composed of same type of secretory units as those of simple glands but have elaborated duct systems that branch rapidly.

2. On the basis of type of secretory product:

a) **Serous:** Secretes a thin watery product

Cells have spherical nuclei near the center.

Secretory granules in acini are called Zymogen granules.

e.g. Parotid salivary gland.

b) **Mucous:** Secretes thick viscous secretion. Flat nucleus is present towards the basal part of

Cells. Cells are filled with- mucous (rich in AMPS). E.g. Sublingual salivary gland.

c) **Mixed:** Seromucus glands. e.g salivary glands of horse.

Both serous and mucous types of cells are present.

They may be

- **Intermixed**, each acini having some serous and some mucous cells.
- Or serous cells may be located at the periphery of mucus-secreting units as half moon shape or crescent shaped cluster of cells called serous demilunes.
- Or mucous tubular unit with a terminal serous acinus.
- Mixture of all mucus scini and all serous acini.

3. On the basis of mode of secretions”

a) **Merocrine (eccrine):**

Product is released as small secretory granules usually enclosed within a membrane referred as granulated vesicles e.g. Prostate of dog.

b) **Apocrine:**

Membrane bound droplet together with a rim of apical cytoplasm and plasmalemma is released from the cell. e.g. Mammary gland.

c) **Holocrine:**

The entire cell is extruded and constitutes a secretory product e.g. Sebaceous glands of skin.

d) Cytocrine:

Secretory material is transferred from one cell to the cytoplasm of another cell. e.g. In epidermis melanocytes transfer melanin pigment into keratinocytes by this mode.

EXERCISE:

1. Q. Draw and labeled the diagram of different types of epithelium.
2. Q. Draw and labeled the diagram of different types of glands.

Practical No. 5

CONNECTIVE AND SUPPORTIVE TISSUE

CONNECTIVE TISSUE:

1. Embryonic connective tissue:

- a) **Mesenchyme:** having irregularly shaped mesenchymal cells with many long processes.
- b) **Gelatinous (muroid) connective tissue:** found in embryonic hypodermis and umbilical cord characterized by stellate fibroblasts type cells. In adult it occurs in the core of the papillae on the reticular folds, omasal laminae, bovine penis, core of roosters comb.

2. Adult connective tissue (Connective tissue proper):

- a) **Loose connective tissue:** Present around blood vessels, nerves, between muscle bundles and layers of smooth musculature of hollow organs. Cells present are-
 - i) **Fixed cells:** Fibrocytes. Mesenchymal cells, adipose cells.
 - ii) **Free cells:** Macrophages, mast cells, plasma cells, melanocytes, lymphocytes, monocytes, granulocytes.
- b) **Dense irregular connective tissue:** Cells are similar to loose connective tissue but fibrocytes predominate. Collagen fibers more crossing at varying angles. This type is found in visceral pleura, capsules of liver, kidney, testis etc. fasciae, aponeurosis, joint capsule, pericardium, dermis, propria of initial portion of digestive system.
- c) **Dense regular connective tissue:**
 - i) **Collagenous:** Fascicles of parallel collagen fibers bound together by loose connective tissue e.g. tendons.
 - ii) **Elastic:** Branching and interconnecting elastic fibers surrounded by loose connective tissue e.g. ligamentum nuchae, elastic fasciae of abdominal musculature of herbivores.
- d) **Reticular connective tissue:** Reticular fibers and cells are abundant found as stroma of all lymphatic organs (spleen, lymph node, hemal node, tonsils), diffuse lymphatic tissue solitary lymphatic nodules, bone marrow.
- e) **Adipose connective tissue:**
 - i) **White fat:** has unilocular adipocytes; found in subcutaneous tissue, foot pads, digital cushions. This acts as thermal and mechanical insulator and as energy yielder.
 - ii) **Brown fat:** has multilocular adipocytes, smaller than white fat cells found in rodents and hibernating mammals; located mainly in axillary and neck regions, along aorta in mediastinum, mesenteries, dorsal to kidney around aorta and vena cava.

Supportive tissue:

- a) **Bone**
- b) **Cartilage**
- a) **Bone:**

Bone is a connective tissue with cells and fibers embedded in a hard unbending matrix (ground substance).

Bone differs from cartilage:

- i) Canalicular system
- ii) Direct vascular supply
- iii) Its growth process (by apposition only)

Macroscopic structure:

In case of long bones three regions are:

- i) **Epiphysis:** enlarged ends covered by hyaline (articular) cartilage.
- ii) **Diaphysis:** hollow cylindrical shaft covered by periosteum. Wall is composed of compact bone that encloses medullary marrow cavity.
- iii) **Metaphysis:** in growing animal, epiphysis and diaphysis are separated by it. It has specialized hyaline cartilage plate called physis.

Microscopic structure:

Shaft consists of bony matrix deposited in lamellae (2-8 μm thick) with lacunae between each layer. The lamella which lines the outer and inner surface of the compact substance are called outer circumferential/periosteal and inner circumferential/endosteal lamellae respectively. Between these two lamellae, the compact tissue contains cylindrical structures called osteons or Haversian system. Each system has a central canal. Haversian canal encircled by circular lamellae. Haversian canal runs longitudinally in long bones and contains blood vessels and nerves.

The lacunae contain bone cells called osteocytes. Radiating from the lacunae are the branching canaliculi that join canaliculi of adjacent lamellae. Haversian canal and Volkmann's canal intervals between Haversian system are occupied by irregular, incomplete lamellae called interstitial lamellae. Definite lines separate it from Haversian system from the periosteal and endosteal surfaces fine channels arise, which pierce the bone and communicate with Haversian canal are known as Volkmann's canal which contain blood vessels and nerves.

Osteocytes lie in lacunae. They are flattened with number of processes, which extend into canaliculi.

Most bones are invested with tough fibroelastic membranous periosteum. Periosteum has outer fibrous layer and inner osteogenic layer that provide cells to form bone.

Periosteum is firmly attached to the bone by bundles of collagen fibers that penetrate into outer circumferential and interstitial lamellae. These fibers are called perforating (Sharpey's) fibers.

Delicate layer of squamous cells, the endosteum, lines the medullary cavity.

b) Cartilage

i) **Hyaline cartilage:**

- Bluish, white, glassy, translucent in fresh state.
- Usually arranged in plates, column or irregular masses.
- All hyaline cartilages except articular ones are covered by perichondrium, having outer fibrous and inner cellular (chondrogenic) layer.
- Chondrocytes are oval or spherical lying in lacunae. In mature cartilage there may be 4 cells in one lacunae called cell nest/isoegenous cell groups.
- Matrix has fine collagenous fibers embedded in amorphous ground substance containing highly sulfated polymerized mucopolysaccharides called chondroitin sulfate.
- Matrix is territorial (area surrounding the cell and inter-territorial area distant from cells lighter having more collagen fibers).

ii) **Elastic cartilage:**

- Yellow in fresh state due to elastic fibers in the matrix.
- Cartilage cells are like cells of hyaline cartilage in ring or groups of 2, 4 or 8 and surrounded by distinct capsule.

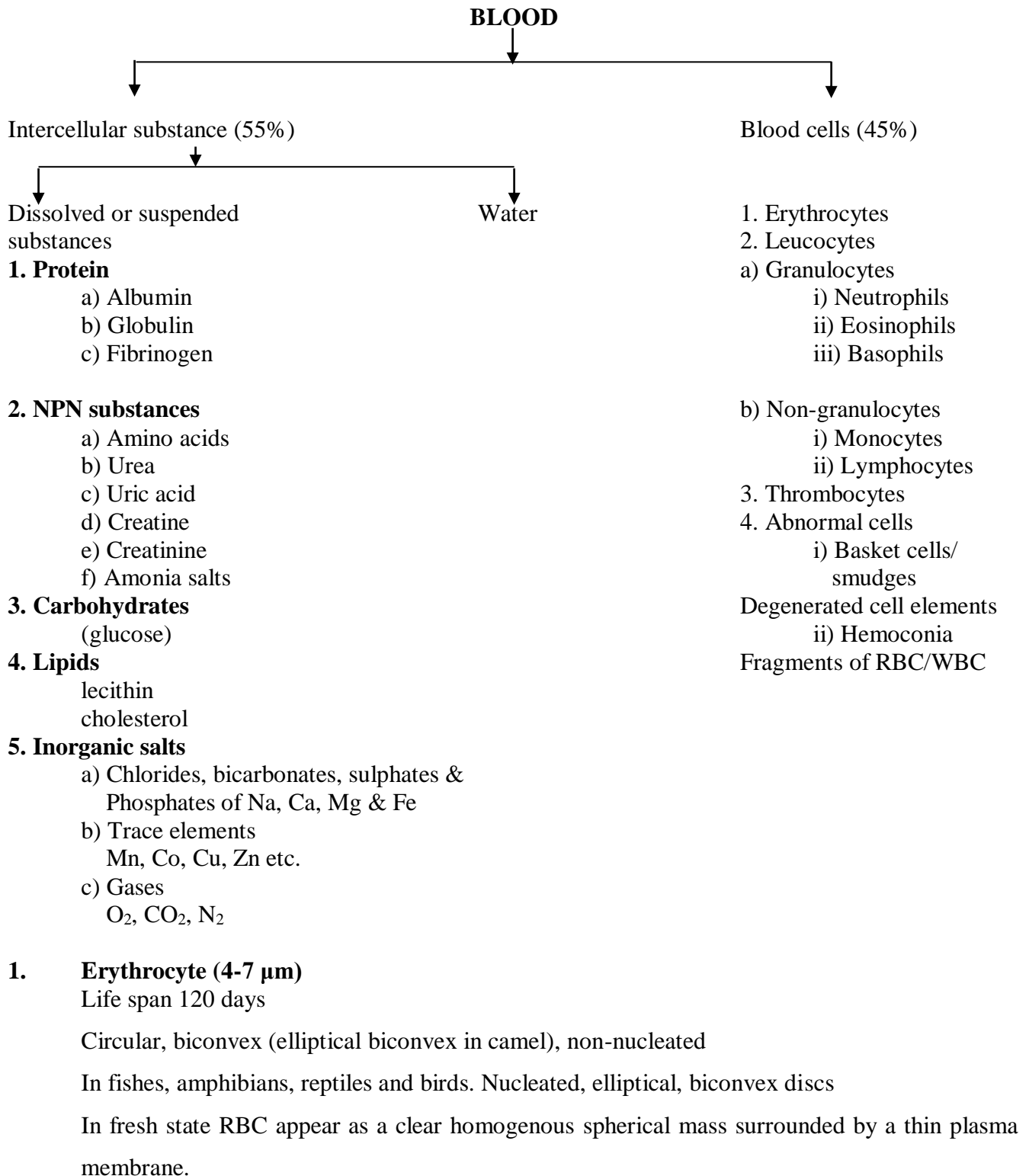
iii) **Fibro cartilage:**

- White in colour and tough in structure.
- The matrix contains coarse collagenous fibers.
- Fibro cartilages provide rigidity, toughness & elasticity also provide. Modes for long bone development.
- Intercellular substance contains numerous branching elastic and a few collagen fibers.

EXERCISE:

1. Draw and labeled the diagram of different types of connective tissue.

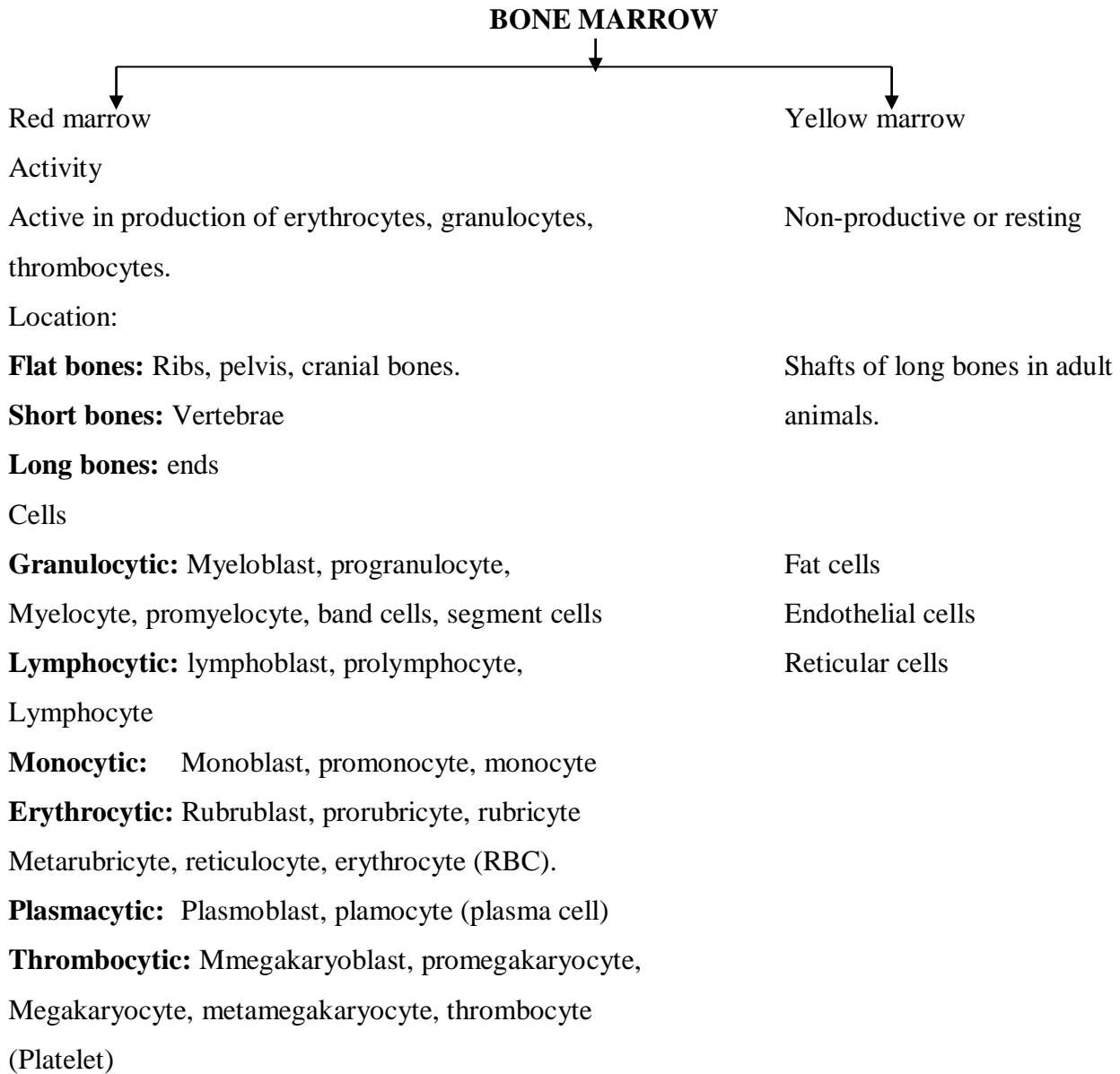
Practical No. 6



2. Leucocytes	Cell type	Size	Nucleus	Cytoplasm/ Granules	Remarks
Granulocytes					
	1. Neutrophils	12-15 µm	2-5 lobed	Fine neutrophilic granules	Slightly basophilic in horse Acidophilic in rabbits, guinea pig, chicken (heterophils) Extrachromatin lobe like a Drumstick is present in female animals-sex chromatin.
	2. Eosinophils	10-15 µm	2-3 lobed	Large eosinophilic granules	Cat uniform rod shaped grayish orange granules Sheep, dog, cow, pig: uniform spherical shaped bright orange granules Horse: largest, mulberry Like appearance, bright orange
	3. Basophils	10-15 µm	2-3 lobed	Large strongly basophilic granules mask the nucleus	Dogs have larger and fewer granules than cow and horse.
Non-granulocytes					
	1. Monocytes	12-18 µm	Bean/Kidney/ horse shoe shaped	Foamy vacuolated	
	2. Lymphocyte				
	a) Large	9-15 µm	Small, round	Mild basophilic vacuolated	Small more in dog and cat both in cow sheep, goat
	b) Small	6-9 µm	Large, round	Narrow blue staining rim in cytoplasm	
	3. Platelets				
	Platelets	2-5 µm	Absent	Granules Pale blue cytoplasm, have clusters of reddish Purple granules	The term thrombocyte is used for nucleated platelets in fish, reptiles and birds.

Lymph:

Lymph is colorless or faintly yellowish saltish fluid running in lymph vessels and has specific gravity 1.022, lymph is composed of lymph plasma and mostly lymphocytes, few erythrocytes, occasionally eosinophils and rarely monocytes.



EXERCISE:

1. Draw and labeled the diagram of different types of blood cells.

Practical No. 7
MUSCULAR TISSUE

Muscular tissue consists of elongated muscle cells called muscle fibers and scanty intercellular substance. Muscle fibers are characterized by their ability to contract on certain stimuli.

Classification:

1. According to function:

Voluntary – skeletal

Involuntary – visceral cardiac

2. According to structure:

Striated or striped – Skeletal and cardiac

Non-striated or unstriped – Smooth or visceral

3. According to both above:

Skeletal, striated, voluntary, red muscle

Visceral, smooth, non-striated, involuntary

Cardiac, involuntary, striated

Skeletal muscle	Smooth muscle	Cardiac muscle
Strongly striated	No striations	faintly striated
Long cylindrical cells	Small, spindle shaped Cells.	Syncytial branched cells. Single cylindrical fibers
Multinucleated, nucleus may be elongated, flattened placed peripherally	Uninucleated, nucleus slender, more elongated, placed centrally	Nucleus single or double, oval, elongated, placed centrally
Myofibrils abundant, distinct Grouped (Cohnheim's areas)	Myofibrils not distinct	Myofibrils distinct
No intercalated disc	No intercalated disc	Intercalated disc present contains Purkinje fibers which are specialized nerve impulse conducting cardiac muscle fibers located under the endocardium. In longitudinal section appear beaded and indistinctly striated

EXERCISE:

1. Draw and labeled the diagram of different types of muscular tissue.

Practical No. 8

NERVOUS TISSUE SYSTEM

Nervous tissue: It is specialized tissue having power of reception, conduction and transmission of nerve impulse.

Nervous system:

Central Nervous system: Brain, Spinal cord.

Peripheral Nervous system: Cranial, Spinal nerves, their ganglia

Autonomic Nervous system: Sympathetic, Parasympathetic nervous system

Nerves and ganglia that innervate viscera are designated as the autonomic NS

Neuron: Nerve cell with its processes is called neuron. Neurons are aggregated in brain, spinal cord and also scattered in eye, ear and olfactory mucous membrane.

Neuron has

Cell body (perikaryon):

Cell body is composed of nucleus and its surrounding cytoplasm. The cytoplasm contains neurofibrils, Nissl bodies (tigroid substance), Golgi apparatus, mitochondria, centrosomes, lipochrome and melanin.

Dendritic zone: Receive stimulus initially. It has highly branched processes called **dendrites**. Each tree like dendrite emerges as a main trunk those branches repeatedly into smaller and smaller dendrite twigs.

Telodendritic zone: Here stimulus is transmitted to other cell.

Axon: Conduct stimulus between upper two zones. Axon is an elongated cylinder with few branches. It originates from the axon hillock of the cell body. **Axon hillock** devoid of chromatophilic substance.

Medullated/myelinated/white nerve fibers: (central NS cerebrospinal nerves)

They **form white matter of brain**, spinal cord

They are composed of

a) **Axis cylinder** – continuation of axon

b) **Myelin sheath** – interrupted at intervals by node of Ranvier absent at organ termination of nerve fiber and in grey matter.

c) **Neurolemma/sheath of Schwann** – covers cerebrospinal nerves as they leave the brain and spinal cord.

Non-medulated /Remak's fibers/grey nerve fibers: (autonomic nervous system, grey matter of brain, spinal cord, olfactory nerve filaments)

The structure of grey nerve fibers is like white fibers except following variations.

a) The neurolemma is absent

b) Node of Ranvier is absent

c) Myelin sheath is absent

According to processes the **neurons are of three types**

1. Unipolar: (Pseudounipolar) Cell body give rise to single axon that soon bifurcates. One function as dendrite other as axon, structurally both are like axon. Unipolar neurons are present in cerebrospinal and dorsal root ganglion. They convey information to the central nervous system.

2. Bipolar: Cell body gives rise to two processes one at either end. Bipolar neurons are present in retina, vestibulocochlear nerve. They convey information to central nervous system.

3. Multipolar: Cell body gives rise to single axon and multiple dendrites. Multipolar neurons are present in grey matter of CNS (brain, spinal cord)

Synapse: Synapse are junction between two neurons. The junction is formed either by the union of dendrites of two or more neurons or by the union of dendrites of one neuron with the axon of other.

Classification

1. Axoaxonic synapse
2. Axodendrites synapse
3. Axosomatic synapse

The synapse is the site of morphologic specialization where one neuron is able to influence the excitability of another neuron, typically by releasing neurotransmitter molecules.

Neuroglia (or supporting tissue)

Comprise more than 90% cells of nervous system.

1. Astrocytes: (or nervous supporting system)

Astrocytes are stellate shaped cells with many long cytoplasmic processes.

Two types:

- a) **Protoplasmic Astrocytes** – Found in grey matter of brain and spinal cord. These are short rayed astrocytes with branching processes.
- b) **Fibrous Astrocytes** – Found in white matter of brain and spinal cord. These are long rayed astrocytes, their processes do not branch.

2. Oligodendrocytes: (or Oligodendroglia)

Found in white and grey matter. These cells are smaller than astrocytes having few processes with less branching. Nuclei are small, spherical, densely stained. In grey matter they serve as perineural satellite.

In white matter they form myelin sheaths around axons.

3. Microglia:

Microglia are few in number and found in the grey matter. They have small cell body, small nucleus covered with a thin layer of cytoplasm. In pathological conditions they enlarge and become elongate, called rod cells or Gitter cells.

4. Ependymal cells:

Ependymal cells line the ventricular cavities of the brain and the central canal of the spinal cord. These are cuboidal or columnar cells joined by zonulae adherents near their luminal borders, which bears microvilli and numerous motile cilia.

Some modified ependymal cells form the choroid plexus epithelium and produce cerebrospinal fluid.

5. Neurolemmocytes: (Schawann’s cells)

Gliocytes of peripheral nervous system that ensheath axons or encapsulate neuronal cell bodies as ganglionic gliocytes or satellite cells.

Ganglia:

Ganglia are aggregations of nerve cells that have left the central nervous system during embryonic development.

Two types:

a) **Cerebrospinal ganglion** are sensory ganglion because it contain **unipolar cells** bodies of afferent neurons (cells bodies are bipolar in vestibulocochlear nerve).

Supporting tissue: Capsules and interstitial tissue (**satellite cells and fibroblasts**) are present.

Neurons: unipolar neurons are present.

b) **Autonomic ganglion** (vertebral, collateral and terminal) is like cerebrospinal ganglion except following difference

- 1) Tone ganglion as they form synapse
- 2) Multipolar neurons
- 3) Satellite or capsular cells absent

Cerebrum:

Cortex (outer layer of grey matter)

Layers	Composition
1. Molecular (or plexiform layer)	Predominately neutrophilic apical dendrites from pyramidal cells and telodendria
2. External granular layer	predominately small neurons
3. External pyramidal layer	Medium and large pyramidal neurons
4. Internal granular layer	Small stellate nucleus
5. Internal pyramidal layer	Medium and large pyramidal neurons
6. Fusiform (multiform) layer	Spindle shaped cells which sends axons into the medulla

Medulla (inner white matter layer): Mostly medullated, few, non-medullated nerve fibers & neuroglia cells.

Cerebellum:

Cortex (outer grey matter layer)

Layers	Composition
1. Outer molecular layer	predominately neutrophilic, dendrites of piriform cells and basket cells
2. Piriform cell layer	Large flask shaped Purkinje’s/piriform cells with basket cell
3. Inner granule cell layer	Granule cells – small neurons

Medulla (inner white matter layer): Mostly medullated, few non-medullated nerve

Fibers, fibrous astrocytes, microglial cells, Oligodendroglia.

Nerve trunk

Medullated nerve:

Medullated nerve is composed of bundles of medullated nerve fibers covered by connective tissue. It consists of following:

Axis cylinder in the center

Medullary sheath covering

Neurolemma sheath or sheath of Schwann

Connective tissue sheaths

Endoneurium – (Henle’s sheath) covers each individual fiber

Perineurium – cover group of fibers called fasciculi or bundles

Epineurium – cover all nerve bundles forming the nerve trunk

Meninges:

Meninges envelope the brain, spinal cord and roots of peripheral nerves, entire optic nerve

Pachymeninx Duramater

Leptomeninges Arachnoid

Pia matter

Epidural space – in spinal region

Subarachnoid space – in brain and spinal region

Spinal cord:

1. Connective tissue covering (or meninges)

Duramater

Arachnoid

Pia matter

2. Spinal substance or matter

Grey matter (Central ‘H’ shaped structure, with dorsal and ventral horns having a central canal in the transverse bar).

White matter (peripheral region)

EXERCISE:

1. Draw and labeled the diagram of different types of nerve cell.

Practical No. 9

CARDIOVASCULAR SYSTEM

Cardiovascular System:

1. Heart:

Endocardium – lined by endothelium subendothelial tissue contain blood vessels and fibers.

Myocardium – muscle fibers of atria, ventricles, specialized fibers of Sinu-atrial node, Atrio-ventricle node, Atrio-ventricle bundle or bundle of his.

Epicardium- reflection of visceral layer of pericardium having mesothelium and a layer of fibroelastic tissue.

2. Elastic arteries (aorta and its immediate large branches)

Tunica intima – Endothelium, layer of connective tissue below the endothelium (sub-endothelium).

Tunica media – Circular elastic fibers, smooth muscle fibers, **internal elastic membrane not separable.**

Tunica adventitia – Thin, coarse elastic and collagenous fibers.

3. Muscular arteries:

Lumen is folded due to internal elastic membrane and heavy muscular coat.

Tunica intima – Endothelium, layer of connective tissue below it.

Internal elastic membrane of elastic fibers clearly evident.

Tunica media – Thick circular smooth muscle bounded externally by external elastic membrane. Well developed in dog, less in sheep, negligible in ox, pig. Absent in horse

Tunica adventitia – Thin, coarse elastic and collagenous fibers.

4. Arteriole:

Tunica intima – Endothelium, internal elastic membrane (may be absent in small arteriole)

Tunica media – About six layers of smooth muscle fibers

Tunica adventitia – Thin, coarse connective tissue

5. Capillary:

Endothelial tube surrounding a lumen of 5-10 μm in diameter.

Fenestrate capillaries: Single layer of fenestrated porous endothelium resting on inconsistent basement membrane.

Fibroblasts, mesenchymal cells and histocyte are surrounding them.

6. Sinuses:

These are vessels with irregular lumen and wall of only endothelium e.g. in sclera as canal of Schlemm, in brain as cranial sinuses, in spleen as splenic sinuses.

When sinuses are lined by single layer of interrupted smooth muscle, they are called Caverns eg. cavernosum urethrae and cavernosum penis.

7. Venule:

Formed by the union of several capillaries

Wall formed by endothelial cell layer surrounded by a tunica adventitia.

Lumen is collapsed and larger than corresponding arteriole.

8. Sinusoid:

Sinusoids have incomplete endothelial lining and irregular lumen.

All endothelial cells are phagocytic thus considered part of the reticuloendothelial system.

Sinusoids are found in bone marrow, liver and certain endocrine organs.

9. Small and medium size vein or muscular vein:

Structure is like arteries of same size with following differences:

a) Thinner wall.

b) large and collapsed lumen.

c) In tunica intima the internal elastic membrane is generally absent. If present poorly developed.

d) Tunica media is relatively thinner than adventitia.

e) Tunica adventitia has longitudinally arranged coarse collagenous and elastic fibers. It is not well demarcated from the tunica media thickest layer.

10. Lymph vessels:

Resemble corresponding veins in structure except with following differences:

a) Their walls are thinner and transparent

b) Lymph vessels have more valves.

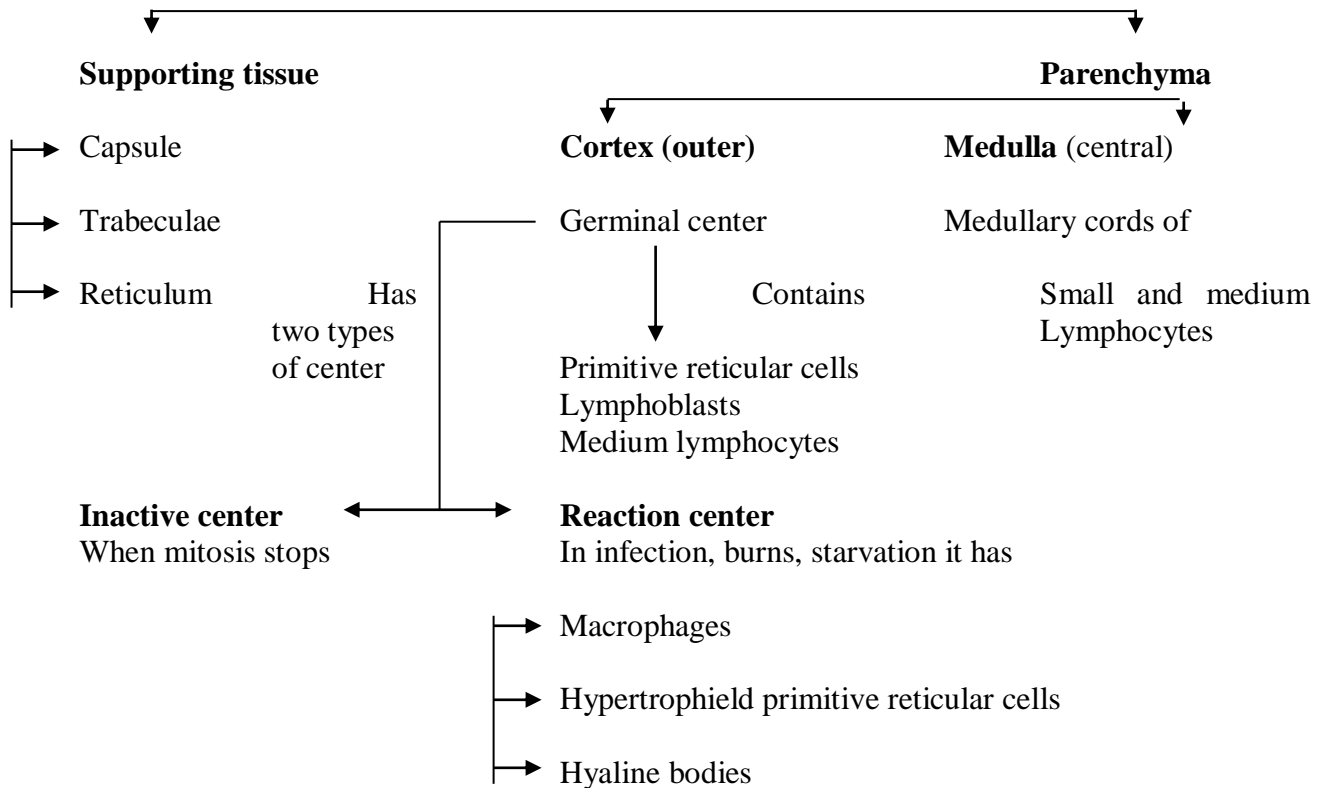
c) Lymph vessels contain lymph (colorless fluid) and lymphocytes.

Practical No. 10

LYMPHATIC ORGANS

Lymphatic Organs:

1. Lymph node:



N.B.

1. In pigs the cortex like tissue is placed centrally and medulla peripherally.
2. In birds lymph nodes are absent. Lymphatic tissue occurs mainly in digestive tract. Waterfowls such as ducks goose have true lymph nodes in cervical and lumbar region.

2. Haemal/haemolymph node:

Haemal nodes are small/oval reddish mass found in ruminants few in pig and absent in horse. Their structure resembles combined picture of lymph nodes and spleen. They are believed to be miniature spleen.

- i) Capsule and trabeculae contain smooth muscle fibers like spleen. The inner portion of the capsule presents many distended capillaries.
- ii) Cortex and medulla are like lymph node.
- iii) Afferent and efferent lymph vessels are absent/inconspicuous but arterial supply and venous drainage are present.
- iv) All sinuses are filled with blood.

True haemal nodes are present in pig because both lymph and blood vessels pour their contents in the sinuses.

3. Tonsils:

Tonsils form a pharyngeal ring around the passage from mouth to pharynx and incomplete ring around the choanae (post nares). There are two types of tonsils.

With crypts/follicular

1. Palatine tonsils of swine, ruminants, horse and man
2. Lingual tonsils of ox, horse, man
3. Tubal tonsils of swine
4. Paraepiglottic tonsil of sheep, goat and swine

Without crypts

1. Palatine tonsils of carnivores
2. Pharyngeal tonsils of all domestic animals.
3. Tubal tonsils of ruminants.

Histological structure:

a) Surface epithelium	Stratified squamous epithelium
b) Supporting tissue	Capsules is poorly organized sends septa. Interstitial tissue or stroma is of reticular C.T.
c) Lymphoid tissue	Lymph nodes arranged in single layer below epithelium. They have large germinal center and a thin shell of density packed small lymphocytes.
d) Associated structures	Lymph vessels Tonsillar glands, Mucous or mucoserous glands. Their ducts Open on mucosal surface. Skeletal muscles.

4. Spleen:

Spleen is largest lymphoid organ. It is like a huge haemal node interspersed in the blood stream. A depression, hilus is present where vessels enter and leave. The parenchyma is not differentiated into cortex and medulla.

Histological structure:

Capsules: Capsule is of thick connective tissue invested by peritoneum. It sends trabeculae into splenic parenchyma of red and white pulp. Reticular fibers also support splenic pulp.

Parenchyma or pulp:

White pulp: This is like lymphatic tissue. Typical lymphatic nodules (splenic or Malpighian corpuscles or nodules) occurs around splenic artery and periarterial lymphatic system. Lighter central area of the nodules is germinal center, which may be absent depending upon its functional state. Principal cells are B-lymphocytes, whereas T-lymphocytes occupy area immediately around the modular artery.

Red pulp: Red pulp is formed of venous sinuses or venules, splenic cords, pulp arteries and sheathed and terminal capillaries. It consists of diffuse lymphocytes, reticular connective tissue, erythrocytes (which imparts red color), monocytes, granulocytes, giant cells, iron pigments.

N.B.

Eosinophils are numerous in horse.

Giant cells are seen in carnivores, pigs and rats.

Heavy deposits of pigment are found in adult horses, swine and ruminants.

Smooth muscle fibers also occur in red pulp of ruminants and swine.

5. Thymus:

Thymus is flat, bilobed mass of lymphoid tissue.

Position:

Foetus: Pharynx to anterior mediastinum

Before puberty: Cervical part of thymus is always present whereas thoracic part sometimes degenerates

After puberty: Thymus completely degenerates except in cattle and dog.

Histological structure:

a) **Supporting tissue:** Capsule sends perpendicular trabeculae into the cortex. Interstitial tissue supports parenchyma and has reticular tissue.

b) **Parenchyma:**

Cortex: Cortex contains densely and uniformly packed small lymphocyte tissue cells called thymocytes. Eosinophils and plasma cells are also seen.

Medulla: Medulla is lighter and less compact than cortex. Lymphocytes are less. Medullary epithelial cells characteristically form thymic (Hassall's) corpuscles, which consists of one or several central calcified or degenerated large cells surrounded by flat keratinized cells in a concentric arrangement, containing many desmosomes and bundles of microfilaments.

EXERCISE:

1. Draw and labeled the histological structure of spleen.

Practical No. 11

Gastrointestinal tract:

1. Mouth or oral cavity:

Mucosa

- (i) Stratified squamous epithelium.
- (ii) Tunica propria
- (iii) Muscularis mucosae absent

Submucosa

- (i) Areolar tissue
- (ii) Compound, tubulo-alveolar submucosal glands present

2. Lip:

Skin

- (i) Keratinized stratified squamous epithelium
- (ii) Sweat and sebaceous gland present on outside.
- (iii) hair follicles present on outside.

Subcutis

Loose areolar connective tissue

Muscularis layer

Composed of orbicularis oris muscle-a skeletal muscle.

Submucosa

- (i) Firm areolar connective tissue
- (ii) Labial glands present

Mucosa

- (i) Stratified squamous epithelium.
- (ii) Tunica propria
- (iii) Muscularis mucosae absent
- (iv) Sub-epithelial capillary plexus.

3. Tongue:

Mucosa

- (i) Cornified stratified squamous epithelium
- (ii) Tunica propria or corium modularity dense irregular connective tissue.
- (iii) Papillae – filiform, fungiform, circumvallate, foliate, Von Ebner's glands in the furrows around fungiform, Circumvallate and foliate papillae
- (iv) Taste bunds in fungiform, circumvallate and foliate papillae, Lingual tonsils.

Submucosa

- (i) Absent on the dorsum of the tongue
- (ii) Small amount present ventrally

Muscles

- (i) Striated muscles present, arranged longitudinally, vertically and transversally and obliquely
- (ii) Centrally connective tissue joins two halves this central line is median raphae. In dogs the raphae presents a fusiform cord called LYSSA, which is composed of fibrous muscular and fatty tissue.

4. Tooth:

- Crown:** Projecting beyond the gum
- Root:** Embedded in maxilla/mandible
- Neck:** (not in horses) Constricted portion between crown and root.

Tooth is composed of

- (i) **Enamel:** Hardest, dense, white, 90% calcium phosphate, covers dentine of the crown.
- (ii) **Dentine:** hard, yellow, elastic substance
- (iii) **Pulp:** Loose connective tissue, stellate cells, odontoblasts, gelatinous substance, blood vessels nerves.
- (iv) **Cementum:** Covers the dentine of the root (crusta petrosa)
- (v) **Periodontal membrane:** Dense irregular fibrovascular connective tissue.

5. Pharynx:

- Mucosa:** Nasopharynx has pseudostratified ciliated columnar epithelium with goblet cells
Oro-and laryngopharyns has stratified squamous epithelium
- Lamina propria:** Fibroelastic connective tissue lymphoid infiltration, pharyngeal tonsils, mucosal glands in oropharyns and laryngopharynx.
- Lamina muscularis mucosa:** absent
- Submucosa:** Present in nasopharynx absent on others
- Muscularis:** Composed of skeletal muscles

6. Oesophagus:

- Mucosa:**
 - (i) Stratified squamous epithelium
 - (ii) Lamina propria – coarse areolar connective tissue
 - (iii) Lamina muscularis mucosa – variable amount of longitudinal muscles

Submucosa:

- (i) Coarse areolar connective tissue
- (ii) Tubulo-alveolar mucous glands
- (iii) parasympathetic submucosal plexus or Meissner's plexus

Muscularis: Composed of skeletal muscles

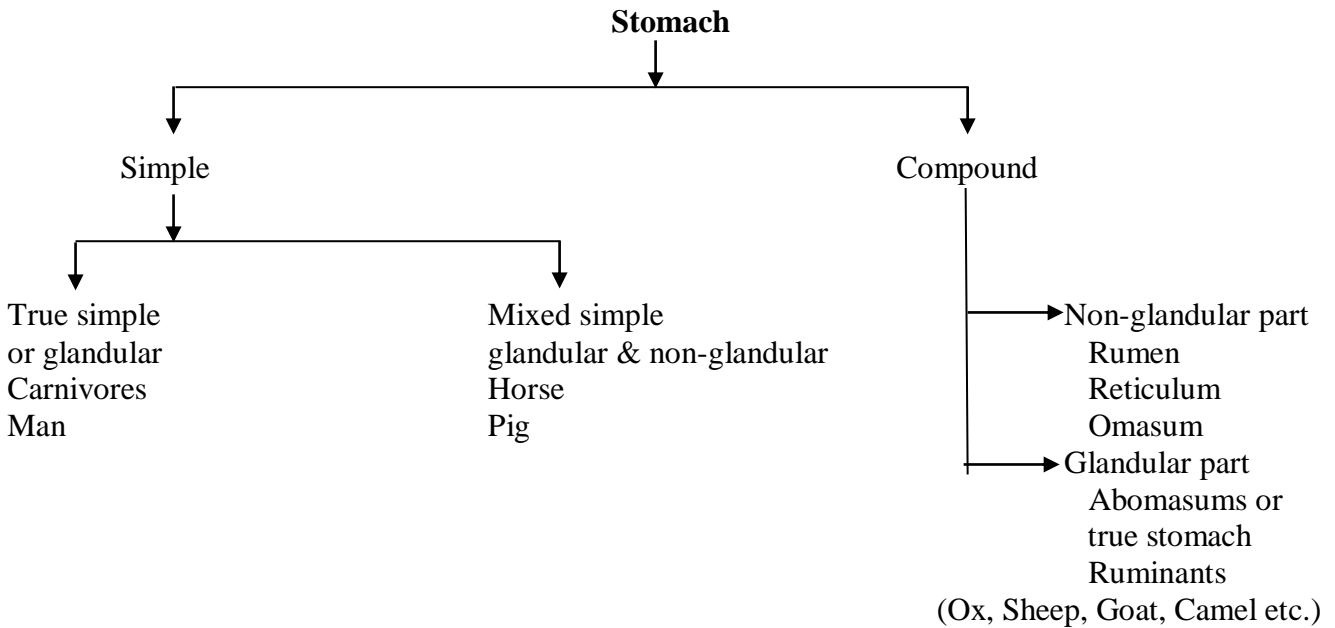
- (i) External longitudinal muscles

(ii) Internal circular muscles

Adventitia/fibrosa/serosa

(i) Serosa (serous membrane in thorax and abdomen)- Thoracic + abdominal parts.

(ii) Adventitia/fibrosa (loose fibroelastic tissue in neck)- Cervical parts.



True simple stomach:

Mucosa:

(i) Mucosa has folds called rugae and gastric areas having gastric pits or foveolae

(ii) Simple columnar epithelium

(iii) Lamina propria – fine collagen and reticular fibers, gastric glands, diffuse lymphocytes, few solitary nodules, some plasma cells, mast cells, eosinophils.

(iv) Lamina muscularis mucosa – 2-3 layers of smooth muscles, inner circular, outer longitudinal. Circular muscles around glands.

Gastric glands: Simple branched tubular glands

(i) Cardiac gland – 3-7 open into each **gastric pit**, secrete **mucus**.

(ii) Fundic gland – 2-3 open into a **single duct**.

Neck – neck cells, secrete mucus.

Body – **Chief or peptic cells** secrete pepsinogen, rennin, lipase, **parietal cells** secrete hydrochloric acid.

(iii) Pyloric gland – Pyramidal cells secrete **mucin**.

Argentaffin/interchromaffin cells secrete intrinsic antipernicious factor

Submucosa: Loose C.T. blood vessels lymphatics, nerves, Meissner's plexus.

Muscularis:

(i) Inner circular (in pyloric orifice form pyloric sphincter).

(ii) Outer longitudinal

(iii) Myenteric or Auerbach's plexus is present between the above two layers of muscles

(iv) In some areas inner most oblique muscle layer is present (in cardiac region forms cardiac sphincture)

Serosa- Peritoneal reflection, inner fibrous, outer mesothelial layer present

Mixed simple stomach:

All structures similar to true stomach except the mucosa, which presents the following differences:

- (i) Mucosa is marked by a line called *margoplicatus* into two areas.
Oesophageal or non-glandular part is lined by stratified squamous epithelium and glandular area exactly like true stomach.

Compound stomach:

Rumen:

- (i) Mucosa non-glandular having stratified squamous epithelium
- (ii) Mucosa presents papillae
- (iii) Muscularis mucosa absent, may be seen in the core of long papillae.

Reticulum:

- (i) Mucosa has macroscopic papillae (5-10 mm length) having connective tissue core
- (ii) Muscularis mucosa present only at the tip of the papillae.

Omasum:

- (i) Mucosa has leaf like folds called laminae omasi (5-20 mm) having double layered folds of muscularis mucosae.
- (ii) Laminae omasi have short, horny papillae having connective tissue core

Abomasum: Similar to true stomach

8. Small intestine:

Small intestine has 3 parts: Duodenum, Jejunum and Ileum. The general structure is same except few variations.

Mucosa

- (i) Minute finger like projections called **villi** and tubular depressions called **crypts of Lieberkuhn** are present.
- (ii) Some circular folds called *plicae ciculares* or *valvulae conniventes* or valves of Kerkring are present.
- (iii) Lined by simple columnar epithelium having columnar, goblet, Paneth and argentaffin cells.
- (iv) Lamina propria consists of reticular connective tissue, reticulocytes, fibroblasts, histiocytes, plasma cells, neutrophils, eosinophils, lymphocytes, solitary lymph nodules aggregated nodules or Peyer's patches (confined to ileum).
- (v) Lamina muscularis mucosa has inner circular, outer longitudinal muscle layers.

Submucosa

Composed of loose connective tissue, blood vessels, nerves, Meissner's plexus. In duodenum submucosal or Brunner's gland are also present.

Muscularis

- (i) Inner circular and outer longitudinal muscle layers
- (ii) Myenteric or Auerbach's plexus are present in between these two layers

Serosa

- (i) Reflection of peritoneum having inner fibrous and outer mesothelial layer

Differential features:**Duodenum**

- (i) Brunner's gland (simple branched tubulo alveolar glands)
- (ii) Villi are low, broad
- (iii) Opening of bile and pancreatic ducts are present

Jejunum

- (i) Brunner's gland absent
- (ii) Villi are longer and slender
- (iii) Plicae circulares if present, well developed
- (iv) Solitary nodules in tunica propria, sometimes in mucosa-submucosa as in swine

Ileum

- (i) Villi are few, short, club shaped
- (ii) Peyer's patches are present
- (iii) Goblet cells numerous, more than jejunum

9. Large intestine:

- (i) It consists of caecum, colon and rectum
- (ii) General structure of the wall is similar to that of small intestine except following variations.

Caecum

Villi, plicae circularis absent

Goblet cells more than small intestine

Crypts of Lieberkühn are longer and closer, but lack Paneth cells.

Solitary aggregated nodules are more near the entrance to the caecum in ruminants and swine and towards the blind end in cow, horse and cat. Narrow longitudinal muscular band called taeniae caeci is present in the caecum of horse and pig. They are formed by thickening of outer longitudinal muscle layer.

.Colon

- (i) Structure is like caecum except few differences.
- (ii) Goblet cells are more than the caecum.

- (iii) Lymph nodules less, when present solitary rather than aggregated only.
- (iv) Taeniae are called taeniae coli in horse and pig.

Rectum

- (i) Structure is like caecum and colon except few differences
- (ii) Solitary or aggregated lymph nodules are present in posterior part of rectum. The ano-rectal junction presents 5-14 longitudinal mucosal folds and aggregated lymph nodules. This area is known as zona columnaris rectalis.
- (iii) Goblet cells are abundant.
- (iv) Rectum is lined by serosa anteriorly and adventitia posteriorly.

Anus

- (i) It is terminal part of the alimentary canal. It is divided into three distinct parts in pig and dog.
- (ii) Zona columnaris analis: Contains longitudinal folds.
- (iii) Zona intermedia: Submucosa has **anal glands**.
- (iv) Zona cutaneous: It is hairless external cutaneous part of anus. It contains **perianal** or **circumanal** glands.

Structure:

Mucosa

- (i) Non-cornified stratified squamous epithelium
- (ii) Tunica propria areolar connective tissue
- (iii) Lamina muscularis mucosa absent

Submucosa

- (i) Non-glandular in horses, ruminants.
- (ii) In pig and dog glands are present. They are simple branched coiled tubular glands.
- (iii) Circumanal glands (sebaceous and pseudoriferous glands) present.
- (iv) In older dogs, especially males, the sebaceous glands cells may become enlarged and polyhedral in type and resemble liver cells and therefore called as hepatoid cells.

Muscularis

- (i) Inner circular muscle thickened to form sphincter ani externus.
- (ii) Outer circular muscle is layer of skeletal muscle and form sphincter ani externus.

Fibrosa

Absent as sphincter ani externus is attached to adjacent skeletal muscles.

10. Anal sacs:

Present in dogs, cats.

Mucosa:

- (i) Stratified squamous epithelium.
- (ii) Tunica propria of loose connective tissue, lymph nodules.
- (iii) Muscularis mucosae absent

Submucosa

- (i) Perisaccular glands are apocrine simple tubular glands lined by simple columnar epithelium.
- (ii) Sebaceous glands present.

Muscularis

Formed by adjacent skeletal muscles.

Liver:

Liver is the largest gland of the body.

1. Supporting tissue:

a. Fibrous capsule: (Glisson's capsule) has fibrous and mesothelial layer.

b. Interstitial tissue or stroma: Capsule sends trabeculae into the substance of the gland and divides it into lobules, which are most distinct in pig and camel. The space enclosed by the lobules, which contains interstitial tissue and hepatic artery, portal vein, bile duct, lymphatic duct and nerves and is called portal canal or portal triad or portal area.

2. Parenchyma:

Parenchyma is composed of many irregular hepatic cords of polyhedral liver cells, which radiate from the central vein of the lobule and anastomose with each other. The liver cells contain one or two vesicular nuclei and variable amount of fat droplets, glycogen and protein granules.

3. Vessels and nerves:

a. Bile duct: Bile capillaries – interlobular bile duct – lobar bile duct – bile duct.

b. Hepatic artery: Hepatic artery – lobar hepatic artery – lobular hepatic artery – interlobular hepatic artery – intralobular hepatic artery – intralobular hepatic artery – hepatic sinusoids or hepatic capillaries.

c. Portal vein: Intralobular hepatic sinusoids – interlobular portal vein – lobular portal vein – lobar portal vein – portal vein.

d. Hepatic vein: Convergence of sinusoids – central vein – sublobular vein – lobar vein – hepatic vein – posterior vena cava.

e. Lymphatics:

f. Hepatic nerves: These are vasomotor unmyelinated fibers of autonomic nervous system.

Gall Bladder:

Gall bladder is pear shaped bile storing sac having blind fundus, body and neck.

1. **Mucosa:** Folds divide the surface into irregular polygonal areas. It is lined by simple columnar epithelium having basal nuclei and microvilli on free surface.
2. **Tunica propria – submucosa:** Composed of loose connective tissue. Mucous glands are present near the neck.
3. **Tunica muscularis:** Formed of irregular network of longitudinal, transverse and oblique smooth muscle fibers.
4. **Tunica serosa:** It is derived from peritoneum.

Pancreas:

Pancreas is encapsulated, lobulated, compound tubuloacinar gland having exocrine (5%) and endocrine (95%) secretory units.

Exocrine part:

1. **Supporting tissue:** Capsule is thin and distinct. Septa divides pancreas into irregular lobules.
2. **Parenchyma:** Consists of acini having basket (myoepithelial) cells, and secretory cells, which are pyramidal shaped having supranuclear zymogen granules.
3. **Ducts:**
 Alveolar ducts lined by simple squamous to cuboidal epithelium.
 Intralobular ducts are non-secretory lined by simple squamous to cuboidal epithelium.
 Lobar ducts lined by simple cuboidal to columnar epithelium with goblet cells.

Endocrine part: (Islets of Langerhans)

Islets are arranged in irregular anastomosing cords composed of five different types of cells.

Type of cells	Occurrence	Characteristic	Secretion
A(α)	5-30%	Red staining granules Insoluble in alcohol.	Glucagon
B(β)	Most numerous	Polyangular granulated cells, Granules soluble in alcohol.	Insulin
C	5%	Precursor of other types of cells.	
D(δ)	Very few	Non-granulated cells	Somatostatin
E	Very few	Small granulated cells, precursor to variety of cells that produce various gastroentero-pancreatic hormones.	

EXERCISE:

1. Draw and labeled the histological structure of different segment of digestive system.
2. Draw and labeled the histological structure of liver
3. Draw and labeled the histological structure of pancreas.

Practical No. 12

Respiratory System:

1. Nasal cavity
2. Pharynx
3. Larynx
4. Trachea
5. Primary bronchi
6. Lungs

1. Nasal cavity: - Vestibular, Respiratory and Olfactory regions.

(A) Vestibular region

- (i) Non-cornified stratified squamous epithelium.
- (ii) Tunica propria- Submucosa like dermis; coarse areolar connective tissue, hair follicles, sweat glands anteriorly, simple branched tubule-acinar glands posteriorly.

B. Respiratory region

- (i) Pseudo stratified columnar ciliated epithelium with goblet cells.
- (ii) Tunica propria-sub mucosa contains loose connective tissue, simple branched tubulo- acinar glands. Arteries and veins are numerous.

C. Olfactory region

- (i) Non ciliated pseudostratified epithelium having sustentacular cells, olfactory cells (hair cells) and basal cells.
- (ii) Tunica propria- Submucosa contains areolar connective tissue, simple branched tubule acinar glands called Bowman's gland. Rich blood supply.

2. Pharynx

(explained in digestive system)

3. Larynx

(i) Anteriorly (pharyngeal side /lingual or oral side) stratified squamous epithelium and on laryngeal / interior side pseudostratified ciliated columnar epithelium (posterior side).

(ii) Tunica propria- submucosa contains loose areolar connective tissue, simple branched tubulo- acinar mucous glands, and solitary lymph nodes.

(iii) Cartilaginous wall formed of epiglottis (elastic), arytenoid, thyroid, cricoids (hyaline) and intrinsic laryngeal muscles.

4. Trachea

(i) Pseudostratified ciliated columnar epithelium with goblet cells

(ii) Tunica propria- sub mucosa coarse areolar connective tissue, simple branched tubulo-acinar mucous glands.

(iii) Cartilaginous wall formed by unbroken but dorsally incomplete C- shaped hyaline cartilaginous ring, gap connected by smooth type tracheal muscles which attach on the external surface in dog, cat and on internal surface in horse, pig, ruminants.

(iv) Tunica adventitia outside, areolar connective tissue rich in elastic fibers.

5. Primary bronchi

- (i) Trachea divides into two primary bronchi. They enter lungs and divide into smaller bronchi.
- (ii) Extra pulmonary bronchi – part of bronchi outside lung (structure similar to trachea).
- iii. Intra pulmonary bronchi – part of bronchi inside lung (structure like trachea except few variations).
 - (a) Cartilaginous ring transform into several cartilaginous plates which encircles the tube.
 - (b) Muscularis mucosa appears and forms a complete ring.

6. Lungs

- (i) Supportive tissue
 - (ii) Pulmonary substance or duct and alveolar system.
 - i) **Supportive tissue**
 1. **Capsule in pulmonary pleura:**
 - i) External mesothelium
 - ii) Internal coarse areolar and elastic tissue.
 - iii) It sends interlobular septa.
 2. **Interstitial tissue-** interlobular septa- coarse areolar elastic fibers.
 - (i) **Interalveolar tissue-** fine areolar tissue and fine elastic fibers. Its tissue demarcates lobes into lobules. Interstitial tissues more in ox and Sheep so distinct lobules in lobes where as they are less in horse pig, dog so indistinct lobules
 - (ii) **Interalveolar tissue-** contains pulmonary macrophage cell called **septal cells**. In alveoli they are called alveolar macrophages. In incompetent heart blood enters into alveoli, RBC start degenerating and its hemoglobin are engulfed by alveolar macrophages. These cells are called **heart failure cells**.
 - ii) **Pulmonary substance or duct system:-** Primary, Secondary and tertiary bronchi
 1. **Mucosa:** Pseudostratified ciliated columnar epithelium with goblet cells to simple columnar .
 2. **Tunica propria-** areolar connective tissue.
 3. **Muscularis mucosa** –spiral smooth muscle fibers
 4. **Sub mucosa-** areolar connective tissue , simple branched tubuloacinar mucous glands
 5. **Cartilaginous ring** –change to irregular plates (large- C, V shaped medium irregular plates)
- Primary, secondary and tertiary bronchioles:-**
1. **Mucosa-** simple columnar to simple cuboidal non ciliated epithelium. No goblet cells.

2. Tunica propria-areolar connective tissue thinner than bronchi.
3. Sub mucosa – areolar connective tissue- thinner than bronchi.
4. Cartilage plates absent.

Respiratory bronchioles

- (i) Simple cuboidal epithelium
- (ii) Tunica propria-sub mucosa negligible.

Alveolar duct

- (i) Simple squamous epithelium
- (ii) Fold point contain knob like structure due to spiraling bands of smooth muscle fibers.

Alveolar sac or atrium

A shared space into which several alveolar sacs open is called. Atrium Similar to alveoli.

Alveoli

- (i) Basic unit of gas exchange is alveolus. Alveoli are essentially spheroid air spaces, they open into alveolar sac, alveolar duct or lumen of a respiratory bronchiole
- (ii) Simple squamous epithelium
- (iii) Surrounded by rich network of capillaries
- (iv) Adjacent alveolus present connections called alveolar pores.

Blood supply

1. Pulmonary arteries and veins
 - (a) Bronchial arteries
 - (b) Lymph vessels

Nerve supply

1. Parasympathetic (vagus nerve)
2. Sympathetic plexus.

EXERCISE:

1. Draw and labeled the histological diagram of lungs.

Practical No. 13

Urinary system:

1. Kidney
2. Ureter
3. Urinary bladder
4. Urethra

1. Kidney :

a) Supportive tissue (Stroma)

Capsules surrounds the Kidney. Consists of coarse areolar connective tissue and few elastic fibers.

1. In ruminants a layer of fat around Kidney is present- Capsula adipose. When collagen fibers predominate in the capsule- capsula fibrosa.
2. Interstitial tissue is composed of loose connective tissue, present around tubules and blood vessels.

b) Parenchyma

1. Parenchyma contains closely packed uriniferous tubules separated by blood vessels and interstitial tissue.
2. Secretory tubules or nephron is the functional unit of kidney.

Nephron has following parts:-

- i) **Bowman's capsule**- lined by simple squamous epithelium in parietal and visceral layers.
Visceral layer has special cells called podocytes.
- ii) **Proximal convoluted tubules (PCT)** – lined by simple cuboidal epithelium, with brush border.
- iii) **Loop of Henle**- has following parts
 - a) Thick descending part is like PCT- but no brush border. Lower height of epithelium.
 - b) Thin segment lined by simple squamous epithelium.
 - c) Thick ascending segment like (DCT) simple cuboidal epithelium.
- iv) **Distal convoluted tubule (DCT)** – lined by simple cuboidal epithelium.

3. Collecting tubule of excretory duct has following parts:

- i. Arched collecting tubule lined by simple low cuboidal epithelium 7-10 of these ducts open in a straight collecting duct.
- ii. Straight collecting duct lined by simple cuboidal epithelium.
- iii. Papillary duct or duct of Bellini lined by simple cuboidal to stratified epithelium.
- iv. Papillary ducts open in the renal papillae. In horses the renal papillae fuse to form renal crest and papillary ducts open in this crest producing area cribosa.

c) Blood supply

- i. Renal artery
- ii. Inter lobar artery
- iii. Arcuate
- iv. Interlobular
- v. Intralobular

- vi. Afferent glomerular arteriole
- vii. Efferent glomerular arteriole
- viii. Arteriole rectal

1. **Ureter:**

(a) **Mucosa**

Lumen is star shaped due to folded mucosa. Lining epithelium is transitional type.

(b) **Tunica propria-submucosa:**

Composed of loose connective tissue having blood capillaries, lymphatics. In horse tubuloacinar mucous glands are present specially in the upper end and renal pelvis. (Glands of littré)

In birds lymph nodules are present in the tunica propria-submucosa.

(c) **Muscularis:**

Three layers of muscles are present

- a) Inner longitudinal muscle layer
- b) Middle circular muscle layer
- c) Outer longitudinal muscle layer

(d) Serosa consists of inner fibrous and outer reticulo cellular layers.

2. **Urinary bladder:**

(a) **Mucosa:**

(i) Lined by transitional epithelium, which has 5-10 layers in contracted condition and 2-3 layers in expanded condition.

(ii) Tunica propria is composed of loose connective tissue.

(iii) Lamina muscularis mucosa has thin interrupted longitudinal muscle layer.

(b) **Submucosa** of loose connective tissue

(c) **Muscularis**

Three layers of muscles are present

- a) Inner longitudinal muscle layer
- b) Middle circular muscle layer
- c) Outer longitudinal muscle layer

(d) **Serosa** consists of inner fibrous and outer mesothelial layers. In retroperitoneal part only fibrous layer is present.

3. **Urethra :**
{

male – Pelvic urethra, penile urethra
Female –pelvic urethra

Female urethra

Transport urine only.

i) **Tunica mucosa**

Mucosa has longitudinal folds

Epithelium is stratified squamous, transitional near bladder.

ii) **Lamina propria- submucosa**

Contains cavernous tissue, lymph nodules, a few urethral glands

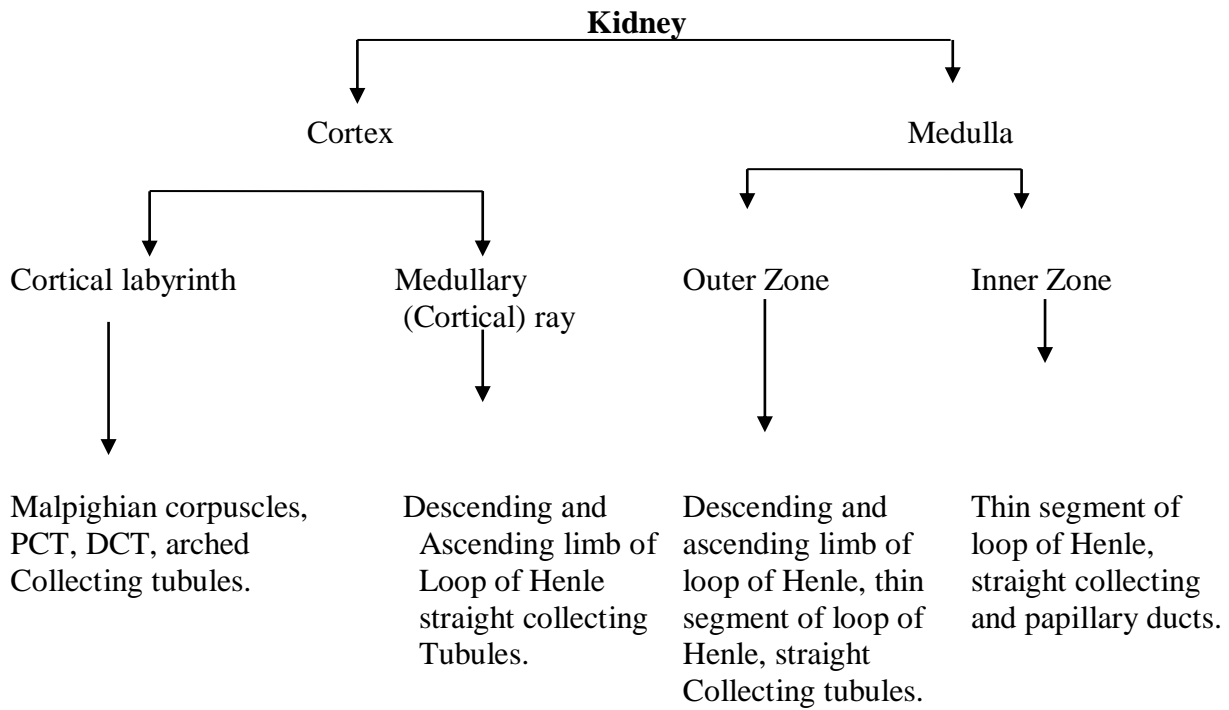
iii) **Tunica muscularis**

Inner circular muscle layer

Ventrolaterally striated urethral muscles blend with constrictor vestibule muscle.

iv) **Tunica adventitia**

Fibroelastic, fuse with surrounding tissue.



EXERCISE:

1. Draw and labeled the histological diagram of kidney.

Practical No. 14

Male reproductive system:

1. Testicles
2. Ductuli Efferentes
3. Epididymis
4. Ductus deferens or vas deferens
5. Urethra and
6. Penis

Accessory sex glands – Seminal vesicles, prostate gland & Bulbourethral gland.

Scrotum – is a cutaneous pouch holding testes in it. It comprises:-

(a) **Skin** – has epidermis of stratified squamous epithelium and dermis having few hair follicles, large sebaceous and sweat glands.

(b) **Dartos** – is modified subcutis, of dense fibrous tissue and bundles of smooth muscle fibers, devoid of fatty tissue.

(c) **Scrotal fascia**

Spermatic fascia derived from oblique external abdominal muscle.

Cremasteric fascia derived from oblique internal abdominal muscle.

Infundibular fascia derived from transverse abdominal muscle.

First two fuse together, third fuse with tunica vaginalis parietalis.

(d) **Tunica vaginalis parietalis**

Composed of loose areolar connective tissue and mesothelium. It is an extension of parietal peritoneum.

Testicles lay in scrotum: it consists of exo- and endocrine glands

(a) **Supporting tissue**

i) **Tunica vaginalis:** visceral layer outer mesothelium and inner areolar tissue.

ii) **Tunica albuginea:** capsule composed of dense irregular connective tissue and highly vascular layer called stratum vasculare.

Tunica albuginea: becomes thick posteriorly in bull and man.

Mediastinum testis: is central longitudinal core of connective tissue riddled with blood vessels in dog and cat & on dorso- anterior parts of tests in horse.

Mediastinum testis sends septa which divide the gland into lobules.

iii) **Interstitial tissue**

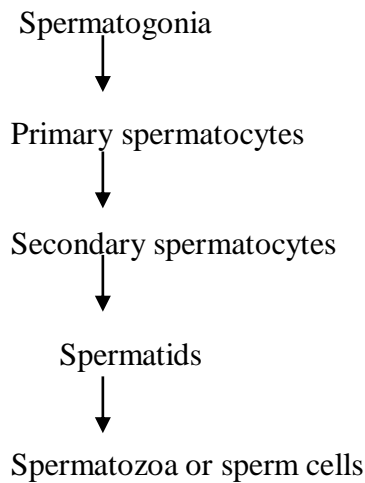
Loose connective tissue around seminiferous tubules. Leydig cells present between the tubules- also called inter tubular cells – secrete testosterone.

(b) **Parenchyma** consists of seminiferous tubules having:-

- Tubuli contorti
- Tubuli recti

- Collecting tubules – rete testis
- Tubuli contorti has

Supporting or sertoli cells. They give attachment to spermatogonia for nourishment. They extend from basement membrane to the lumen of the tubules. Spermatogenic cells are arranged in different layers



- Tubuli recti contains simple cuboidal cells and/or Sertoli cells
- Rete testis are irregular interanastomosing canals in the mediastinum, (if present) lined by simple low columnar, cuboidal or even squamous epithelium. They join the ductuli efferentes.

1. **Ductuli efferentes or vasa efferentia** has 6-20 tubules, which after leaving testicle converge to form the head of epididymis. Each tubule has:

Mucosa: Epithelium is high columnar ciliated and low columnar non-ciliated in alternate groups.

Tunica propria: of loose connective tissue.

Tunica muscularis: has thin layer of smooth muscles which blends with surrounding connective tissue.

2. **Epididymis** has head (caput), body (corpus) and tail (cauda).

Head consists of ductuli efferentes and rest part consist of a single duct of epididymis.

Pseudostratified columnar epithelium with non-motile stereocilia.

Tunica propria-submucosa is very thin.

Tunica muscularis has circular muscle layer, thickness increases towards vas efferent

Tunica adventitia is thin, blend with surrounding connective tissue.

3. **Ductus deferens or vas deferens** has non-glandular part and glandular part.

a) **Non- glandular part**

Mucosa: Pseudo stratified non-ciliated columnar epithelium.

Tunica propria-submucosa: loose connective tissue.

Tunica muscularis: is thick smooth muscle having inner circular and outer longitudinal layers of smooth muscle.

Tunica serosa: Loose areolar connective tissue and mesothelial layer.

b) **Glandular part(ampulla ductus deferentes)**

Absent in boar, cat and dog

Present in horse, bull, ram and goat

Mucosa: Pseudostratified columnar surface epithelium and simple cuboidal glandular epithelium.

Tunica submucosa: loose connective tissue. Contains simple branched tubulo-alveolar merocrine gland. Secrete yellowish white gelatinous fluid.

ACCESSORY SEX GLANDS

1. Seminal vesicles

Horse, boar, man – compound tubular, vesicular/saccular

Ruminants – Compact, lobulated and coiled tubular.

Dog, cat – absent

a) Parenchyma

Mucosa: Has primary, secondary, tertiary folds.

Lining epithelium is simple columnar in stallion and boar pseudostratified columnar in ruminants.

Cells of ducts – in beginning similar to glandular part of seminal vesicle, then stratified columnar and finally transitional like urethra.

Tunica propria – submucosa: Loose connective tissue.

Tunica muscularis: Inner circular and outer longitudinal muscle layers.

Tunica adventitia: Fibro elastic, rich in blood vessels and nerves.

b) Supporting tissue

Capsule: Loose connective tissue

Interstitial tissue – Fibroelastic

Interlobular septa: Well developed and muscular in bull. Less developed in stallion.

2. Prostate gland :

Corpus prostaticae – at neck of the urinary bladder.

Pars disseminata – embedded in tunica propria- submucosa around urethra under urethral muscles.

Bull, boar : Small body and relatively large pars disseminate.

Stallion, dog: Large body and small para disseminate.

a) Supporting tissue

Capsule

Interlobular septa

Interstitial tissue- fibroelastic

b) Parenchyma

Compound tubular gland in horse, boar and cat

Compound tubulo- alveolar gland in ruminants.

Epithelium:

Tubule/alveoli lined by simple cuboidal to columnar (depending on secretory phase) corpora amylacea concentrations may be seen in alveoli of old animals.

Ducts – simple cuboidal to columnar epithelium throughout, but transitional epithelium near urethra.

Tunica propria – submucosa – Loose connective tissue

Tunica muscularis : circular muscle fused with inter lobular septa

Prostate secretion increases sperm movement

Alkaline secretion of prostate neutralizes the acidity of semen due to production of CO₂ by sperm respiration.

3. Bullourethral gland

Located dorsolaterally at the posterior end of the urethra, near ischial arch under the cover of urethral muscle.(Skeletal muscle).

Present in stallion, bull, boar & cat. Absent in dog.

a) Supporting tissue

Capsule – of areolar tissue

Interlobular tissue trabeculae from capsule which divide parenchyma into irregular lobules.

Trabeculae consists of coarse areolar tissue and smooth muscles but in horse striated muscle fibers (urethral muscles) also seen.

Interstitial tissue: Scanty, fibroelastic with few smooth muscle fibers.

b) Parenchyma

Contains merocrine glands.

In hose, boar compound tubular mucous glands

In ruminants man compound tubulo alveolar mucus glands

EpitheliumTubules/alveoli are lined by simple columnar epithelium.

Large ducts have pseudostratified columnar to transitional epithelium

Tunica propria has loose areolar connective tissue.

Secrete mucus, but in horses more serous secretion.

Secretion clears and lubricates urethra prior to ejaculation. In boar waxy gelatinous secretion acts as a plug of reproductive canal to prevent backflow.


Male urethra -Three parts:-

A. **Prostatic** : Urinary bladder to caudal edge of prostate.

B. **Membranous** : Extends from caudal edge of prostate to where urethra enters the bulb of penis.

C. **Spongiose:** From bulb of penis to the external urethral opening.

Male urethra



Sex glands open into it.

Near bladder a dorsolateral fold is present in urethral duct which ends into a prominence called **colliculus seminalis**. Following ducts open on the colliculus seminalis in different species:

Ruminants, stallion	-	Ejaculatory ducts
Boar	-	Ducts deferens, ducts of vesicular gland
Carnivores	-	ductus deferens

Between these ducts, vestiges of fused paramesonephric ducts- the uterus masculine may be found as solid epithelial cord/short canal.

Histological structure:

- **Lined by transitional epithelium** in beginning, thereafter pseudostratified columnar epithelium.
- **Tunica propria-submucosa** has loose and elastic tissue and occasionally lymphatic tissue specially in bull stallion, cat has simple tubular mucous (urethral) glands. Does have lymphatic nodules. Erectile tissue present throughout due to endothelial lined caverns. It constitute vascular stratum in prostatic and membranous urethra.
- Tunica muscularis has smooth muscle near bladder and striated muscles in remainder urethra.
- Tunica adventitia comprised of loose or dense irregular connective tissue.

In ruminants and stallions the terminal part of urethra protrude incompletely (bull) or completely (stallion, ram and buck) above glans penis to form processes urethras, which is covered by cutaneous mucus membrane.

4. Penis

Penis has root, body and glans

Penis consists of

- a) Paired corpora cavernosa penis.
- b) Corpus spongiosum surrounding spongy urethra.
- c) Glans penis

a) Paired corpora cavernosa penis

It is surrounded by tunica albuginea, a thick layer of dense irregular connective tissue. A connective tissue septum divides corpora cavernosa penis completely (stallion, dog) or partially. Tunica albuginea sends trabeculae in corpora cavernosa penis to form cavernous spaces.

Tunica albuginea and trabeculae consist of mostly white fibrous tissue in bull and boar. In stallion and dog in addition to white fibrous tissue it also contains smooth muscle fibers, so penis is softer in texture.

Caverns: caverns are lined by endothelium. Their blood supply is from arteries with helical arrangement. Helicine arteries have epithelioid smooth muscle cells in tunica interna that protrude into the lumina of these vessels as ridges or pads, causing partial obliteration. As smooth muscles relaxes, the blood flow into caverns increases considerably causing erection.

Stallion	-	vascular penis	predominance of caverns
Bull, boar	-	Fibroelastic penis	caverns less extensive

		Connective tissue prevails
Dog, cat	-	intermediate type
		contains bony/ cartilaginous tissue
		Bony penis – dog

b) **Corpus spongiosum** surrounding spongiose urethra.

c) **Glans penis**

Glans penis is well developed in stallion and dog. It is surrounded by tunica albuginea rich in elastic fibers. A continues into trabeculae that delineate spaces containing erectile tissue similar to that of corpus spongiosum penis (stallion) or a plexus or large caverns (dog) Glans is covered by prepuce.

Species characteristics:

Dog:

Corpora cavernous penis are completely separated by septum of connective tissue. It is continued cranially by the penis, which terminates in fibrocartilagenous tip.

Glans has bulbous glandis and pars longa glandis. Bulbous glandis has large caverns separated by connective tissue trabeculae. Pars longa glandis forms rostral protion of glans, having by identical structure to glans. Both surround the penis in distal portion of spongiose urethra and is assoated with corpus spongiosum.

Cat:

Adipose cells between caverns of corpus cavernosum penis . Small os penis surrounded by corpus cavernosum of glans.

Stallion:

Corpus cavernosum contain many elastic fibers and smooth muscle cells. Glans covers the corpus cavernosum penis rostrally and possesses a long, caudally directed dorso-median process and an enlargement the corpora glandis, the covering of which bears cylindrical papillae.

An indentation of glans the fossa glandis contains a slightly protruding end of urethra.

At the level of glans urethral muscle bundles are interrupted by retractory penis muscle.

Boar:

Characterized by corkscrew type of spiral penis. Structural details of penis are like bull.

Bull:

Corpus penis has central connective tissue strand formed by converging trabeculae. Tip of penis consists of mesenchymal cells adipose cells, large intercellular spaces. Extensive erectile venous plexus present.

Buck, Ram:

Structure like bull

Glans is large cap like enlargement tuberculate.

Two lateral outpocketings of corpus spongiosum penis protrude from it laterally.

5. **Prepuce:** Prepuce is a tube like reflection of skin. External layer is typical skin having sebaceous glands. It reflects inwards to form internal layer.

Ruminants and boar have bristle like hairs externally.

EXERCISE:

1. Draw and labeled the histological diagram of different segments of male genital system of ox.

Practical No. 15

Female reproductive system:

1. Ovaries
2. Oviducts or uterine tubes or fallopian tubes
3. Uterus
4. Vagina
5. Vulva
6. Mammary gland

1. Ovaries

Ovaries are two in number and are combined exocrine and endocrine glands.

A. Cortex (outer portion)

- i. **Germinal epithelium:** simple cuboidal/columnar (young) low cuboidal/squamous (adult) through out surface – but in mare – (ovulation fossa)
- ii. **Stroma:** supporting tissue:-
 - i) tunica albuginea
 - ii) Interstitial tissue

iii) **Ovarian follicles** in different stages of development i.e primary secondary and tertiary.

Mature follicle has:-

- a) Theca folliculi:-
 - Theca externa (fibrous layer)
 - Theca interna (cellular vascular layer)
 - Basement membrane
- b) Membrana granulosa
- c) Liquor folliculi in the antrum (central cavity)
- d) Ovum having corona radiata, Zone pelluciada, vitelline membrane, vitulus or cytoplasm nucleus or germinal vesicle with prominent nucleous or germinal pore.
- e) Corpus luteum (CL) CL can be of following types:
 - Ruptured follicle with little clotted blood. Corpus hemorrhagicum.
 - Then with proliferation of follicular cells. Corpus luteum.
 - If pregnancy doesn't occurs it is called corpus spurium or CL of ovulation (cycle)
 - If pregnancy occur it is called corpus luteum verum or CL of Pregnancy.
- f) Corpus albicans corpus luteum degenerates in due course becomes corpus albicans which is a remnant of corpus luteum.
- g) Follicles: Most of the follicles undergo atresia. Degeneration takes place in following order:
 - Ovum
 - Membrana granulose
 - Theca interna invade membrana granulosa
 - Finally follicle filled with reticular fibers and connective tissue cells.

B. **Medulla (central portion)** of ovary consists of:-

- (i) Rich coiled blood supply so called Zona vasculosa.

- (ii) Loose connective tissue stands of smooth muscle fibers.
- (iii) Mesovarium
- (iv) Large convoluted arteries
- (v) Veins
- (vi) Lymphatics
- (vii) Nerves
- (viii) Rete ovarii (in ruminants, carnivores)

Vestiges of rete ovarii in the form of blind irregular tubes are seen lined by simple cuboidal epithelium. Sometimes cellular cords are seen.

Secretions and functions: Estrogen, Progesterone

1. Exocrine gland:

- a) Estrogen: from theca interna androgens which results in released estrogen from granula cells.
- b) Progesterone: from corpus luteum and placenta.

2. Oviduct or uterine tube or fallopian tube:

Oviduct has three parts.

- (i) **Infundibulum** : large funnel shaped part having fimbriae.
- (ii) **Ampulla** : Thin walled section, highly coiled mucosa with secondary and tertiary folds.
- (iii) **Isthmus**: A narrow segment, no secondary and tertiary folds.

Histological structure:

i. Epithelium.

Simple columnar/Pseudostratified columnar with motile cilia.

ii. Lamina propria-submucosa

Loose connective tissue with many plasma cells mast cells, eosinophils

iii. Tunica muscularis

Inner circular

Outer longitudinal (more thicker towards uterus)

iv) Tunica serosa

Tunica serosa is reflection of peritoneum having fibrous and mesothelial layers.

3. Uterus:

Uterus has three parts:

- i. Two horns or cornua
- ii. Body or corpus
- iii. Neck or cervix

Histological structure of cornua and corpus

(I) Endometrium (Tunica mucosa):

a) Epithelium

Simple columnar in mare, bitch & queen

Simple columnar/pseudostratified columnar in sow & ruminants

b) Lamina propria-submucosa

- Loose connective tissue, highly vascular, glandular (Uterine glands)
- Uterine glands are simple, branched tubular glands lined by ciliated and non-ciliated
- Simple columnar epithelium.
- Glands are absent in carbuncular region in ruminants.

(ii) Myometrium (tunica muscularis)

Inner thick circular muscle layer

Outer thin longitudinal muscle layer

In between the above two layers at places stratum vascularae is present having arteries veins and lymphatics

iii. Perimeterium (Tunica serosa)

Inner loose connective tissue layer

Outer mesothelium

Histological structure of cervix

i. Tunica mucosa:

Circular and longitudinal mucosal folds are present, plica palmatae.

Epithelium: simple columnar with many mucigenous cells including goblet cells.

In ruminants intraepithelial and subepithelial glands are present

In sow 90% of cervix has vaginal type of mucosa with stratified squamous epithelium.

ii. Lamina propria-submucosa

Contains collagenous, few elastic fibers

iii. Tunica muscularis:-

Inner circular muscle layer with elastic fibers.

Outer longitudinal muscle layer

iv. Tunica serosa:

Loose connective tissue

A longitudinal duct of epoophoron (Garter's duct) may be present in this layer on one or both sides.

4. Vagina

Portion of genital tract between uterus and vulva.

Histological structure

(i) Mucosa

Longitudinal mucosal folds are present. In cow, prominent circular folds in cranial portion of vagina are present.

Epithelium: stratified squamous. In mare polyhedral cells with a thin layer of flattened cells on the surface are found.

(ii) Lamina propria-submucosa:

Loose or dense irregular connective tissue:

Lymphatic nodules are present in caudal part of vagina.

- (iii) Tunica muscularis:
 Inner thick circular muscle layer
 Outer thin longitudinal muscle layer
 In sow, bitch another inner longitudinal muscle layer is present.
- (iv) Tunica adventitia (Anteriorly serosa):
 It has collagen and elastic fibers, blood vessels, nerves, ganglia.

5. Vulva (Urogenital sinus):

Urogenital sinus can be differentiated into three regions:

- i. Vestibule
- ii. Clitoris
- iii. Labia vulvae

(i) Vestibule

- (a) Stratified squamous epithelium:
- (b) Lamina propria-submucosa has loose connective tissue, many subepithelial lymph nodes; especially near clitoris, major (Bartholin's) vestibular glands.
- (c) Major vestibular glands (homologous to bulbourethral glands of male) are present in deep part of mucosa-submucosa in ruminants and queen. These are bilateral, compound, tubulo-acinar mucous glands.
- (d) Minor vestibular glands are homologous to the male urethral glands.
- (e) In mare and bitch and erectile corpus cavernosum called bulbus vestibule in present it resembles corpus spongiosum penis.

(ii) Clitoris

- a) Clitoris consists of erectile tissue corpora cavernosa clitoridis (homologous to the corpora cavernosa penis of male) it is well developed in mare.
- b) A rudimentary glans clitoris is present which is functionally erectile only in mare.
- c) A preputium clitoris is present.
- d) A nonerectile fibroelastic tissue (cover) replaces glans in queen sow and ewe.

i. Labia vulva

- a) Labia vulvae forms vulva. Labia vulvae are two curved vertical lips enclosing vulvar cleft, rima vulva (or fissure magna) and joining at dorsal and ventral commissure.
- b) Labia vulvae are covered by skin richly supplied with apocrine sweat and sebaceous glands.
- c) Striated muscle fibers of constrictor vulvae are found in hypodermis.
- d) In sow and bitches vulva are congested in estrus.

6. Mammary gland

Compound tubuloalveolar gland.

Corpus mammae:

i. Skin

Contains epidermis dermis

Sebaceous and sweat glands are present.

ii. Supporting connective tissue

a) Suspensory apparatus

Two lateral suspensory ligaments

Two medial suspensory ligaments

b) Interstitial tissue

Interlobar and intralobar connective tissue is present.

Interstitial tissue is more in old age, poor health and less lactation. This type of udder with more interstitial tissue is called as fleshy udder.

iii. Parenchyma

Consists of alveoli and duct system

a) **Alveoli:** Lined by simple cuboidal epithelium. Myoepithelial cells are present, which contract on stimulation by oxytocin.

b) **Ducts**

c) **Intralobular** (low columnar-cuboidal epithelium, less secretory activity)



Lobular (low columnar-cuboidal epithelium, no secretory activity)



Interlobular (low columnar-cuboidal epithelium, no secretory activity)



Lobar (two layered stratified squamous to cuboidal epithelium)



Gland cistern (two layered stratified cuboidal epithelium)

(or lactiferous sinus or milk cistern)

d) In ruminants the order is: Lactiferous sinus – Teat sinus/cistern –papillary duct (teat canal, lactiferous duct or steak canal) External surface of teat.

Lactiferous ducts

Pig, horse	2-3
Cat	4-7
Dog	7-16
Cow Buffalo	1

EXERCISE:

1. Draw and labeled the histological diagram of different segments of female genital system of cow.

Practical No. 16

ENDOCRINE SYSTEM:

1. Pineal gland (epiphysis):

It is follicular parenchymatous organ attached by a stalk to the diencephalon.

Supportive tissue

Capsule: Thin, formed from pia mater. Trabeculae having occasional melanocytes are given into the gland. These divide the gland into lobules in most of the animals.

Interstitial tissue: Neuroglia cells and striated muscle fibers.

Parenchyma contains

Pinealocytes: Large cells with small processes and homogenous protoplasm.

Astrocytes: Their processes surround pinealocytes.

Ependymal cells: Line the pineal recess (extension of third ventricle).

Intercellular deposits (brain sand or corpora arenacea) occur after puberty.

2. Pituitary gland (Hypophysis):

Hypophysis (Pituitary gland)

Hypophysis (Pituitary gland)		
Adenohypophysis		
	Neurohypophysis	
<p>Originate as a dorsal evagination of the roof of the embryonic Pharynx.</p>	<p>A ventral outgrowth of the diencephalic (hypothalamic) floor. A distinct round/ovoid structure on caudodorsal portion of the gland.</p>	
<p>Pars distalis Bulk of gland</p>	<p>Pars intermedia Closely apposed to Neural lobe</p>	<p>Pars tuberalis Sleeve around the median eminence</p>

Pars distalis

Cells	Frequent Occurrence	Characteristics	Granule Size	Hormone
1. Chromophils A. Acidophils (i) Somatotrophs	Lateral portion of pars distalis	Granules stain orange with orange G stain.	300-400 nm	Somatotrophic hormone (STH)
(ii) Lactotrophs	Throughout pars distalis	Cells stain with Erythrosin and carmine. Affinity more in pregnancy and lactation.	800 nm	Prolactin or leuteotropic hormone (LTH)

B. Basophils

(i) Thyrotrophs	Midventral region of pars distalis	Cells stain with Aldehyde-Fuchsin. Also PAS (+ve).	150 nm	Thyroid stimulating hormone (TSH)
(ii) Gonadotropes	Throughout pars distalis	Granules and with Alcian Blue, Aldehyde Thionin. Also weakly PAS+ve.	200 nm	Follicle stimulating (FSH) and Leutinising (LH) hormone in female. Interstitial cell stimulating (ICSH) in male.
(iii) Corticotrophs	Throughout pars distalis	Difficult to locate in light microscopy PAS+ve.	150-200 nm	Adreno-cortico trophic (ACTH), β -Lipoprotein.

2. Chromophobes

Follicular cells	Line follicles No granules
Stellate cells	Present interspersed between other cells Have numerous processes. No granules
Third type cells	Considered a resting granulated form of all other granulated cells.

Pars intermedia:

Cells types are:

- i) Large, pale-staining cells surrounding colloid follicles.
- ii) Typical pars distalis cells (especially ACTH cells)
- iii) Follicular cells
- iv) Stellate cells
- v) Low cuboidal cells that line hypophysial cleft.

Hormones secreted are Melanocyte stimulating hormone (MSH). Lipoprotein hormone (LPH).

In mammals function is unknown. In amphibians it secretes intermedine which expand melanocytes and darkens the skin.

Pars tuberalis:

- Clusters of epithelial cells often forming small follicles.
- Traversed longitudinally by the wide hypophysial portal vessels that receive tributaries from the primary capillary plexus in the median eminence.
- Few gonadotropes and thyrotrophs are also present.

Consists of follicles of varying size (20-500µm) filled with colloid substance. Follicular cells are low cuboidal in inactive and high cuboidal/columnar in hyperactive gland. In follicular cells the cytoplasm is basophilic. Nucleus is round/oval and central. Sometimes few inclusions such as colloid droplets (iodinated glycoprotein), fat globules, vacuoles, lipochrome pigment are seen. Follicular cells secrete hormones thyroxine (T₄), tri-iodothyroxine (T₃) and di-iodothyroxine (T₂).

Parafollicular cells or **C cells** are derived from the neural crest. Usually single cell, may form groups especially in dogs. These cells secrete thyrocalcitonin.

4. **Parathyroid gland:**

In mammals usually four in number (2 on each side), developed from the outgrowth of the entoderm of 3rd and 4th pharyngeal pouches.

In horse and ox one pair is located cranio-dorsally to the lateral lobe of the thyroid on either side and the 2nd pair is embedded in their deep faces.

In birds they are only pinhead sized yellowish white structure embedded in the loose connective tissue at the back of the thyroid gland which is located at thoracic inlet.

Histological structure:

A) **Supporting tissue**

a) **Capsule:** Capsule is thin, composed of loose connective tissue. It sends thin trabeculae, which divide the gland into lobules.

b) **Interstitial tissue:** It is composed of loose connective tissue having many capillaries.

B) **Parenchyma:**

Parenchyma is highly vascularized. Cells are arranged in irregular cords, strands or clusters.

Two types of cells are present.

- i) Principle cells are small, densely packed cells. Lipofuchsin inclusions (cattle) or glycogen (cat) may be present. In active stage the cytoplasm becomes darker with secretory granules, nucleus is dark staining. These cells secrete parathormone.
- ii) Oxyphil cells are larger cells present rather regularly in the horse and large ruminants but rare in other domestic mammals.

5. **Adrenal gland:**

Adrenal gland is composed of two distinct portions, an outer cortex of mesodermal origin and an inner medulla, derived from neuroectoderm. In amphibian, reptiles and birds both parts are mixed. In lower vertebrates they have separate existence. Adrenal glands (two in number) lie on right and left side, anterior to kidneys either capping them or lying close to them. In ruminants and swine they are flesh colored due to less lipid content. In horse, dog, cat and small lab animals they are yellowish or cream coloured due to high lipid content.

A) Supporting tissue:

a) Capsule: Capsule is composed of dense irregular connective tissue. It sends thin trabeculae, which penetrates the cortex but rarely enter the medulla.

b) Interstitial tissue: Form framework of cortex and medulla by reticular fibers.

B) Parenchyma:

Cortex:

i) Zona glomerulosa:

In ruminants it is formed of irregular, clusters and cords of cells. In horse, donkey, carnivores and pig, this zone is called **zona arcuata** because the cells are arranged in arcs, with their convexity directed towards periphery.

In horse and donkey the cells are tall columnar cells, they are much smaller in the other domestic mammals. They have spherical/ovoid nucleus surrounded by homogeneous cytoplasm. Acidophilic granules of unknown significance are present in the bovines.

ii) Zona intermedia:

Occurs in horse, dog and cat and to a lesser degree in cow, sheep and goat. This is a transitional zone of small undifferentiated cells placed in between zona glomerulosa and zona fasciculata.

iii) Zona fasciculata:

Zona fasciculata consists of radially arranged cords of cuboidal or columnar cells usually one cell layer in thickness. Foamy appearance of the cells (spongiocytes) is caused by of numerous vacuoles due to the dissolution of lipid droplets during routine processing. Nuclei are larger and vesicular.

They secrete glucocorticoids (cortisol and corticosterone).

iv) Zona reticularis:

Zona reticularis is an irregular network of anastomosing cell cords. The cells are polyhedral and are almost similar in morphology to the cells of zona fasciculata, they contain fewer lipid droplets but more lipofuscin, however their nuclei are hyperchromatic and often pyknotic.

Medulla:

The endocrine (chromaffin) cells of the medulla are modified sympathetic neurons. These cells are arranged as irregular cord and clusters separated by a dense network of sinusoidal capillaries. In horse, cow, sheep and pig, the medulla is subdivided into two distinct zones. Outer zone of large, intensely stained epinephrine secreting cells and inner zone of clusters of small polyhedral non-epinephrine secreting cell.

EXERCISE:

1. Draw and labeled the histological structure of Thyroid gland and Adrenal gland.

Practical No. 17

SPECIAL SENSE ORGANS:

EYE (ORGAN OF SIGHT)

Tunics:

1. Fibrous coat (tunica fibrosa):

a) **Sclera:** Sclera is a layer of dense irregular connective tissue having collagen bundles, few elastic fibers and fibroblasts, melanocytes in some areas. The optic nerve leaves the eye through numerous perforations in a disk like area called **area cribosa sclerae**.

b) **Cornea:** Cornea consists of five layers:

- i) Anterior epithelium: Stratified nonkeratinized squamous epithelium.
- ii) Subepithelial basement membrane.
- iii) Substantia propria or stroma of layers (about 100) of collagen fibers having fibroblasts. Amorphous substance has chondroitin sulfate and keratin sulfate.
- iv) Posterior limiting membrane (Descemet's membrane)
- v) Corneal endothelium: Single layer of hexagonal cells.

Corneoscleral junction is calles limbus. Blood vessels supplying the cornea are located here. Normal cornea is devoid of blood vessels.

2. Vascular coat (tunica vasculosa bulbi):

a) **Choroid:** Anteriorly continuous with ciliary body. Ora serrata (junction between retina and ciliary epithelium) overlies the junction between choroid and ciliary body. Outer to choroid is sclera and on its inner side is pigmented layer of retina.

Choroid is subdivided into five layers:

- i) Suprachoroid layer or epichoroid having bundles of collagen and few elastic fibers.
- ii) Vascular layer (stratum vasculare) of numerous arteries and veins separated by stroma.
- iii) Tapetum lucidum: Light reflecting layer located mainly on the dorsal half of the fundus of eye. In herbivores it is fibrous having collagen and fibroblasts. In carnivores it has flat polygonal cells that appear brick like in cross section. In swine tapetum is absent.
- iv) Choriocapillary layer is a dense network of capillaries immediately adjacent to the pigmented epithelial layer of retina.
- v) Basal complex (lamina vitrea, glassy membrane, Bruch's membrane). It separates the choroid from retina.

b) **Ciliary body** is the direct continuation of choroid beginning at ora serrata. It consists of ciliary ring, ciliary process and ciliary muscles.

Various layers of the ciliary body are following:

- (i) Suprachoroid with ciliary muscle (smooth muscle).

- (ii) Vessel layer: Continuation of same layer of choroid.
- (iii) Lamina vitrea or basal complex is continuation of same layer of choroids. It gradually disappear towards the rostral third of ciliary body.
- (iv) Pigmented epithelial layer: It is continuous with the same layer of retina. It consists of highly pigmented cuboidal/columnar cells.
- (v) Non-pigmented layer of cuboidal/columnar cells.
- (vi) Inner limiting membrane is continuation of same layer of retina.

Aqueous humor is thin, clear fluid similar to blood plasma. It has low protein content.

c) Iris: Iris is located ventrally to the lens and separates the anterior and posterior chambers, which communicates through a central opening, the pupil. Iris consists of following layers:

- (i) Anterior endothelial layer: Continuation of the endothelium of cornea.
- (ii) Stroma of pigmented, highly vascularized loose connective tissue.
- (iii) Anterior stromal layer: determines the color of iris and is composed of fibrous stroma and chromatophores.
- (iv) Sphincter and dilator papillary muscles, dilator pupillae.
- (v) Posterior pigmented layer: continuation of nonpigmented epithelial layer of ciliary process.

In ungulates, several dark masses, called granula irridica are found at the dorsal (larger granula) and ventral papillary margins. Numerous capillaries are present in granula.

3. Neuroepithelial coat (*tunica interna bulbi*):

a) **Retina (pars optica retinae)**

Retina is a sensory portion having following layers:

- (i) **Pigment epithelium** having simple squamous/cuboidal epithelial cells.
- (ii) **Layer of rods and cones.** Rods are responsible for vision for shape and movement in dim light whereas cone cells function in bright light and are responsible for colour vision.
- (iii) **External limiting membrane** separates the layer of rods and cones from the outer nuclear layer. It is not a true membrane, but rather attachment sites (terminal bars).
- (iv) **Outer nuclear layer** contains cell bodies and nuclei of the rods and cones.
- (v) **Outer plexiform layer** composed of rod spherules and cone pedicles (the axonal terminations of the photoreceptor cells), the processes of horizontal cells, and the dendrites of the bipolar cells.
- (vi) **Inner nuclear layer** contains nuclei of horizontal cells, rods, cones and amacrine cells.

- (vii) **Inner plexiform layer** having synapses between rods, cones, amacrine and ganglion cells.
- (viii) **Ganglion cell layer** composed of single layer of large multipolar ganglion cells, among which are scattered neuroglia cells.
- (ix) **Optic nerve fiber** layer formed by axons of the ganglion cells, numerous neuroglial cells, Muller's fibers.
- (x) **Internal limiting membrane** formed by apposition of expanded bases of Muller's fibers.

Area centralis retinae is a small round or oval area of the retina located dorsally and laterally to the optic disc. It is characterized by.

- (i) Increased number of cones.
- (ii) Thickening of inner plexiform layer.
- (iii) Increased number of ganglion cells.
- (iv) Thinning of the optic nerve fiber layer.
- (v) Absence of large blood vessels.

The area centralis retinae is the **area of most acute vision** and correspond to the area of the macula and fovea in primates.

b) Blind portion that is epithelial in nature and covers the ciliary blood vessels.

4. Lens:

Lens is a transparent, biconvex structure situated between iris and vitreous body and suspended by zonular fibers to the ciliary body.

- (i) **Lens capsule:** It surrounds the lens. It consists of lamellae of collagen fibers alternating with basal lamina material.
- (ii) **Lens epithelium** is a layer of simple cuboidal epithelial cells. Their bases face lens capsules and apices face the lens fibrils.
- (iii) **Lens fibers:** The lens epithelial cells interdigitate heavily, especially at the equator, where they elongate and differentiate into lens fibers. They lose nuclei, become prismatic or hexagonal in cross section.

Vitreous body:

Vitreous body occupies the posterior compartment, the space between lens and retina. It is a hyrogel containing 98-99% water. It contains network of sparse collagen fibers that is concentrated at the retinal internal limiting membrane, forming the posterior hyloid limiting membrane, and is concentrated anteriorly forming anterior hyloid membrane across the anterior face of the vitreous body. Vitreous body also contains hyaluronic acid and acidic mucopolysaccharides.

EXERCISE:

1. Draw and labeled the histological structure of eye.

Practical No. 18

EAR (ORGAN OF HEARING)

1. EXTERNAL EAR

External ear is covered on both sides by thin skin containing sweat and sebaceous glands and hair follicles. The cartilage is perforated by blood vessels.

External auditory canal is irregular in contour, lined by skin having small hair follicles, sebaceous and ceruminous glands. It is supported by elastic cartilage in the outer portion and by bone near the tympanic membrane.

Ceruminous glands are simple coiled tubular apocrine sweat glands, more towards the lower third of the meatus.

Cerumen or ear wax: Sebum + ceruminous gland secretion + desquamated cells of stratified squamous epithelium.

2. MIDDLE EAR

Tympanic cavity contains three ossicles, their muscles, ligaments and is lined by simple squamous/cuboidal epithelium, few cells are ciliated, particularly those on the floor of the cavity.

Tympanic membrane delimits the external auditory canal from tympanic cavity. It is covered externally by stratified squamous epithelium and internally by simple squamous epithelium. A thin connective tissue layer separates the two epithelial layers.

Ossicles:

Malleus attached to tympanic membrane and incus.

Incus articulates with malleus and stapes.

Stapes attached to the incus and vestibular membrane.

Auditory tube

It connects the tympanic membrane to the nasopharynx, lined by ciliated pseudostratified columnar epithelium (with goblet cells). The tube is surrounded by bone near tympanum and incomplete cartilagenous tube towards the pharynx. Propria in cartilagenous portion contains seromucous glands. At pharyngeal extremity tubal tonsils are present.

In horses auditory tube extends ventrally to form guttural pouch, which is like pharyngeal portion histologically but lacks cartilagenous support.

3. INTERNAL EAR

Internal ear is composed of

1. Bony labyrinth

It is a system of bony canals and cavities within the petrous part of the temporal bone.

2. Membranous labyrinth

It is a series of membranous ducts and sac filled in bony labyrinth.

Between the two is the perilymphatic space filled with perilymph. The membranous ducts and sacs are filled with endolymph and lined with simple squamous epithelium.

The underlying loose connective tissue is continuous with the trabeculae, which span the perilymphatic space and anchor the membranous labyrinth to the bony wall.

Membranous labyrinth:

a) Vestibular portion (organ of equilibrium): Anterior to it is cochlea and semicircular canals posteriorly.

(i) Semicircular ducts: Three in number, anterior, posterior and lateral, lying at right angle to each other. Each duct has sense organ sensitive to angular acceleration and deceleration, called crista ampullaris. It has sensory hair cells and sustentacular cells. Sensory cells have 40-80 stereocilia and one kinocilia.

(ii) Sacculle and utricle give off ducts (utrículosaccular ducts) that join to form the endolymphatic duct, which terminates as the endolymphatic sac. Lateral wall of the utricle (macula utricululi) and medial wall of the sacculle (macula sacculi) are receptor organs. They have sensory hair cells and supporting cells. The sensory cells penetrate into a gelatinous mass, which has CaCO_3 crystals called OTOLITHS. Orientation of head in a gravitational field and control posture, gait and equilibrium are facilitated.

b) Cochlear portion:

Bony cochlea: Osseous canal makes several turns around an axis of spongy bone called the modiolus. Number of turns in dog-3 ½, cat-3/1¼, horse – 2 ¼, cow – 3 ½, man – 2 ¾. Bony canal is partially divided by a bony projection, spiral lamina having upper vestibular lip and lower tympanic lip.

Membranous labyrinth extends into bony cochlea from sacculle by a small duct and ends as a blind sac at the apex of the cochlea.

Scala media divides the osseous cochlea into two parts:

Dorsal component – Scala vestibuli

Ventral component – Scala tympani

Both are joined by an opening helicotrema, and filled with perilymph. Scala media is filled with endolymph.

Vestibular (Reissner) membrane separates the scala vestibuli and scala media. On scala vestibuli side it is lined by simple squamous mesothelial cells and on scala media side by simple squamous epithelium.

Basilar membrane separates scala media and scala tympani. On scala tympani side it is lined with simple squamous epithelium and on scala media side spiral organ of hearing is present. Third wall of scala media is formed by stria vascularis lined by stratified cuboidal epithelium which becomes simple cuboidal epithelium at its junction with spiral organ. This point is called spiral prominence.

Spiral organ (organ of Corti) rests on scala media side of the basilar membrane. The receptor organ has three main components:

- (ii) Sensory cells that transform mechanical energy into electrical energy.
- (iii) Supportive structure for sensory cells.
- (iv) Afferent and efferent nerve terminals.

The cell types present are:

- (i) Border cells – columnar cells.
- (ii) Inner and outer pillar cells.
- (iii) Inner and outer hair (sensory) cells – except these all other cell types are supportive.
- (iv) Inner and outer phalangeal (Deiter's) cells.
- (v) Outer lining (Henson) cells.
- (vi) External supporting (Claudius) cells.

EXERCISE:

1. Draw and labeled the histological structure of ear.

Practical No. 19

INTEGUMENT (SKIN)

A. EPIDERMIS:

Epidermis is stratified squamous keratinized epithelium (ectodermal in origin). Different layers in the epidermis are following:

a) **Stratum basale (Stratum germinativum)**

Single layer of columnar/cuboidal cells on a basal lamina.

b) **Stratum spinosum (prickle cell layer)**

Several layers of irregular polyhedral cells. Secrete a protein involucrine. Which provide structural support to cells.

c) **Stratum granulosum**

Several layers of flattened cells lying parallel to the epidermal & dermal junction. This layer contain irregularly shaped non-membrane bound, electron dense keratohyaline granules. They play role in keratinization and barrier (protective) function. Another lamellar/membrane coated granules/lamellated bodies are found in this layer, These form intercellular lipid component of a complex stratum corneum barrier which prevents penetration of substances from the environment and the loss of body fluids.

d) **Stratum lucidum** (clear layer)

This layer is found in thicker and in hairless regions (e.g. plantar and palmar surface, planum nasale). Several layers of fully keratinized, closely compacted, dense cells in which nuclei and cytoplasmic organelles are absent. Cells have protein bound phospholipids and eleidin in cytoplasm.

e) **Stratum corneum**

This layer contains several layers of completely keratinized dead cells, which are constantly being used and don't have nuclei and cytoplasmic organelles.

Stratum disjunction is term used sometimes for outermost layer of stratum corneum.

Keratinization:

Keratinization is the process of differentiation of keratinocytes.

- Basal epithelial cells undergo mitosis and migrate upwards.
- The volume of the cytoplasm increases and differentiation products (tonofilaments, keratohyaline granules and lamellated bodies) are formed in large amounts.

- As the cellular contents increase, the nuclei disintegrate and the lamellar bodies discharge their contents into intercellular spaces coating the cells.
- The remaining organelles disintegrate and filaments and keratohyaline arrange themselves in bundles.
- Final product of this differentiation and keratinization lay in stratum corneum, which consists of thick plasma membrane limited protein rich cells containing fibrous keratin and keratohyaline surrounded by the extracellular lipid matrix.

B. DERMIS:

Consists of dense irregular connective tissue with a network of collagen, elastic and reticular fibers embedded in an amorphous ground substance. Cells types common are fibroblast, mast cells and macrophages. Plasma cells, chromatophores, fat cells, extravasated leukocytes are often found. Blood vessels, lymph vessels, nerves are present. Sebaceous, sweat glands are also present. Dermis can be divided into thin superficial papillary layer and thick deep reticular layer, but there is no clear-cut demarcation.

C. HYPODERMIS

Consists of loose connective tissue having collagen and elastic fibers. Fat tissue in this layer, may create a cushion/pad of fat called **panniculus adiposus**, e.g., pork bacon and fatback. Large fat deposits are at carpal, metacarpal and digital pad, as they act as shock absorbers.

Hair follicles:

Hair follicles are formed by the growth of the ectoderm into the underlying mesoderm of the embryo.

It has four major components:

- (i) Internal root sheath.
- (ii) External root sheath.
- (iii) Dermal papilla.
- (iv) Hair matrix cells – compose most of the hair bulb.

Arrector pilli muscle:

Arrector pilli muscle is formed by bundles of smooth muscles, which inserts in the connective tissue sheath of the hair follicle and extend towards epidermis, where hair protectson the surface of the skin.

EXERCISE:

1. Draw and labeled the histological structure of skin.

Practical No. 20

PLACENTATION

Placenta is the structural and functional relation (opposition/ attachment) between the embryonic and uterine tissues or between the fetal and maternal tissues for the purpose of physiological exchange.

The manner of formation and attachment of the placenta is termed as placentation.

Classification:

1. Vascular origin:

- i) Omphaloid or yolk sac placenta.
- ii) Allantoic type placenta.

Yolk sac develops before the allantois and hence the omphaloid placenta develops before the allantoic placenta. In early period they coexist.

- iii) Chorioallantoic type placenta.

When the allantois fuses with the chorion, allantochorion is formed resulting in CHORIO ALLANTOIC PLACENTATION.

2. Feto-maternal relationship:

The degree to which the fetal membranes are anchored to the endometrium determines the amount of the uterine tissue loss at the parturition. On this basis.

- i) Deciduate type

Part of endometrial stroma, (the decidua), is shed with the fetal membranes after the parturition.

- ii) Non-deciduate type

No part of endometrial stroma is lost.

3. Morphologic classification:

- a) On the basis of shape of distribution of chorionic villi

Type	Characteristics	Examples
i) Diffuse	Uniformly distributed villi	Sow, mare
ii) Cotyledonary	Cotyledons (tufts of chorionic protrusions) attach to caruncles (endometrial prominences) to form placentome	Ruminants
iii) Zonary	Villi are arranged in the form of band around the equator of the chorionic sac.	Carnivores
iv) Discoid	Villi are present in disc shaped area of fusion.	Man, apes, rodents

b) On the basis of internal structure

The enhancement of the capacity of feto-maternal exchange by enlargement of the surface area is affected in three ways, thus constituting three types of placenta.

Type	Characteristics	Examples
i) Folded	Macroscopic folds, plicae and macroscopic folds or ridges of different order are present in placenta.	Sow
ii) Villous	The fetal component forms arborizing chorionic villi with vascular mesenchymal tissue	Mare, ruminants
iii) Labyrinthine	The allantochorion forms an intercommunicating maze, containing anastomosing blood channels.	Carnivores, rodents

c) On the basis of layers of the interhemal membrane

Fetal component of chorioallantoic placenta has three tissue layers:

- i) Endothelium
- ii) Mesenchyme
- iii) Trophoblast

Maternal counterpart has also three layers.

- iv) Uterine surface epithelium
- v) Connective tissue
- vi) Endothelium

On the basis of layers present or absent in the interhemal membrane the placenta can be divided into following:

Type	Characteristics	Examples
i) Epitheliochorial	All six layers (I to vi) are present.	Sow,
ii) Syndesmochorial	Layer of uterine surface epithelium (iv) is absent.	Ruminants
iii) Endotheliochorial	Uterine surface epithelium and connective tissue (iv & v) absent.	Bitches
iv) Hemochorial	All three maternal layers (iii) is exposed to the maternal blood.	Women, rodents
v) Hemoendothelial	Fetal endothelium is exposed to maternal blood (ii to vi) absent.	Rabbit

EXERCISE:

1. Draw and labeled the histological structure of placenta of different domestic animals.

Practical No. 21

Structure of Hen's Egg

1. Cytoplasm:

A little cytoplasm at the animal pole hence called disc of protoplasm (Germ disc/germinal spot) and abundant yolk at vegetative pole hence called **telolecithal egg**.

Yolk – yellow and white yolk, arranged in concentric layers, outermost layer is always of white variety.

Latebra – flask shaped core of white yolk at the center, Latebra extends from center to protoplasmic disc/blastoderm and flares out under it into a mass called nucleus of Pander.

2. Nucleus or germinal vesicle, nucleolus or germinal spot

3. Cell membrane or viteline membrane.

4. Other coverings:

- a) Zona pellucida or thick transparent membrane, periviteline space between the two membrane.
- b) Albumen – except chalaza, homogenous, but denser near the yolk. Chalaza is twisted portion of more dense albumen.
- c) Shell membranes – inner and outer, air space between two membranes at wider end of the egg shell, outer shell membrane is porous and hence air passes from outside to the air space, chick punctures the inner shell membrane with its beak and breath in the air space till hatching out.
- d) Shell – calcareous covering of egg.

EXERCISE:

1. Draw and label the structure of Hen's Egg.

Practical No. 22

MALE AND FEMALE GAMETES

Sperm of bull:

The average length of ruminant's sperm is 75 μm . In light microscope we can see the head and tail of the sperm. With the electron microscope, the tail is seen to subdivide further into neck, middle piece, principal piece and end piece.

Head: The shape of the nucleus determines the shape of the head. The acrosomal cap with an outer and an inner acrosomal membrane that fuses at the caudal end covers anterior pole of the nucleus. The acrosomal cap contains several hydrolytic and proteolytic enzymes. These enzymes are set free during the acrosome reaction of capacitated spermatozoa in the uterine tube. Acrosomal enzymes are needed for the penetration of the zona pellucida during fertilization. There is narrowing of the cap and condensation of its contents at the caudal end. There is an implantation groove at the caudal end of the head where tail is inserted.

Neck: It is short connecting piece between head and middle piece. It consists of a centrally located centriole and nine peripheral longitudinally oriented coarse fibers with the outer fibers of the middle piece.

Middle piece: The core of the middle piece has characteristic structure of a flagellum i.e. two central microtubules and nine peripheral doublets making up the axial filament complex. They are surrounded by nine longitudinally oriented, tapered outer fibers that are connected to the fibers of the connecting piece. These in turn are surrounded by the mitochondria in a helicoidal arrangement. An annulus of middle piece marks the limit between middle piece and principal piece.

Principal piece: It is the longest part of the sperm having middle piece like composition. The fibers are subject to variations in size and shape and gradually tapers towards the end of the principal piece. The helicoidal arrangement fuse to two of the outer fibers to form the characteristic peripheral fibrous sheath of the principal piece.

End piece: The termination of the fibrous sheath marks the beginning of the end piece which contains only axial filament complex. Proximally in the end piece, this complex has its characteristic nine plus

two arrangement, distally the peripheral doublets gradually become reduced to singlets and terminate at various levels.

Structure of ova of cow:

The ovum of cow develops in the ovarian follicle and is located superficially in the cortex. Follicles appear as bulging on the surface of the ovary. The secretion of the granulosa cells from intercellular cleft leading to the formation of follicular space, the antrum, which is occupied by liquor folliculi and is under turgid pressure. A primary oocyte is surrounded by the granulosa cells at one end called cumulus oophorus, which is continued with granulosa cells. The oocyte has centrally or eccentrically placed round to oval vesicular nucleus with evenly distributed chromatin granules. It has large hyperchromatic nucleolus. A well-developed zona pellucida is present around the oocyte. Outer to the zona pellucida a well-developed corona radiata is present, which has high cuboidal cells. The cell processes from corona radiata and oocyte enter the zona pellucida. The cells of the membrana granulosa enclose the antrum, which is filled with liquor folliculi. A thick basement membrane lies between the thecal layer and the membrana granulosa. Around the basement membrane the steroidogenic cells arranged concentrically form theca layer. Blood capillaries are present within the wall, which divides the theca layer in inner cellular theca interna and outer fibrous theca externa. The granulosa cells are the source of 18β estradiol and estrone. The theca interna cells are the source of androgens.

EXERCISE:

1. Draw and labeled the structure of sperm of bull.
2. Draw and labeled the structure of ova of cow.

Practical No. 23

CHARACTERISTIC FEATURES IN DEVELOPMENT OF CHICK

Formation of Hen's egg:

1. **Ovary** – by 7-9 days, telolecithal ovum containing large yolk and scanty cytoplasm ovulates.
2. **Oviduct** – by 24-25 hours produces all non-yolk components.
 - (a) **Funnel** – 15 minutes, site of fertilization.
 - (b) **Magnum** – 3 hours, secretes thick albumen, egg is rotated due to spirally arranged folds in the wall of the oviduct producing chalaza.
 - (c) **Isthmus** – 1 ¼ hours, lays inner and outer shell membranes.
 - (d) **Uterus (shell gland portion)** – 19-20 hours, produces shell, shell pigment, and releases water to form thin albumen.
 - (e) **Vagina** – 1-10 minutes, expulsion of egg. If egg reaches the cloacal end during the middle of the day it is usually laid at once, otherwise it is likely to be retained until the following day.

Maturation, Fertilization, Cleavage and Gastrulation:

As ovum enters oviduct maturation starts by giving off 1st polar body; at the time of fertilization in infundibulum. 2nd polar body is given off. Deposition of egg constituents and cleavage occur simultaneously. **First phase of gastrulation and formation of ectoderm is completed before the egg is laid down.**

There is no further development in laid down egg unless it is incubated. On the commencement of incubation 2nd phase of gastrulation starts.

10 to 24 hours or one day incubated embryo:

1. **By 10-12 hours** – area opaca, area pellucida, primitive streak and primitive groove are formed.
2. **By 16-18 hours** – head process, notochord, neural plate, proamnion, region, head fold, primitive gut appears.
3. **By 20-22 hours** – anterior intestinal portal, 1st pair of somite by 21st hour and 2nd pair of somite by 22 hours (**age of the embryo in hours = 20 + number of pairs of somites**), neural groove and folds & subcephalic pocket are formed.
4. **By 24 hours** – 4-5 pairs of somites are formed, area vasculosa appears, primitive streak becomes short and faint, omphalomesenteric (vitelline) veins appear. Heart is seen as straight tube. Neural folds approaching to close, eleven neuromeric enlargements seen.

24 to 36 hours embryo:

1. **By 25 hours** – 7 pairs of somites, neural tube with both ends open formed. Prosencephalon prominent with bulging optic vesicles. Forgut shows no change except an increase in size. Somites, show cavity (myocoel) and divide into dermatome, myotome and sclerotome. Coelom formed, heart straight double tube, ventral and dorsal aortae formed.
2. **By 28-30 hours** – 9 pairs of somites, anterior neural pore constricts, heart starts pulsating and bending, neural folds still not closed, oral plate not broken.
3. **By 33-36 hours** – 12-15 pairs of somites, neural folds closed, prosencephalon well differentiated, optic vesicles connected with diencephalon, anterior neuropore closed, posterior neuropore (sinus rhomboidalis) still open, anterior intestinal portal communicating with yolk sac, indistinct 4 divisions of heart formed (36 hours), precardinal veins (33 hours) and post cardinal veins (33-38 hours) formed, 1st pair of aortic arches formed, head process bends towards yolk, auditory placodes formed (36 hours).

36-48 hours or 2 days incubated chick embryo:

1. **By 38 hours** – 17 pairs of somites, ventrally flexed, head turning slightly to left, optic stalk constricts, between 5 to 16 somites pronephric tubules and duct formed, lens placode formed, sinus venosus dilates into atrium, U shaped cardiac tube starts forming ventricles.
2. **By 45-48 hours** – (25-27 pairs of somites)
 - (a) **General feature** – Cephalic flexure well marked fore brain and hind brain becomes parallel, whole embryo lies on the left, cervical flexure appears and embryo appears C shaped, lateral fold and then tail fold appear.
 - (b) **Central nervous system** – Primitive brain vesicles distinct, anterior vesicle constricts and forms telencephalon and diencephalons, middle vesicle remains undivided, posterior vesicle differentiates into metencephalon and myelencephalon, spinal cord closed and fossa rhomboidalis disappears.
 - (c) **Sense organs** – Optic cup and lens vesicles formed, auditory placode becomes otocyst or otic vesicle.
 - (d) **Digestive system** – Fore, mid and hind gut distinct, mid gut opened, hind gut not folded until 3rd day, stomodium and pharyngeal membrane formed. Rathkey's pouch appears. Three pair of pharyngeal pouches, branchial grooves and branchial arches formed, first transitory aperture i.e. brachial cleft appears by rupturing first closing plate and correspond to gill clefts of fishes, thyroid primordium appears, oesophagus, stomach and duodenum not yet distinguishable, liver appears at the junction of fore and mid gut.
 - (e) **Cardiovascular system** – Four regions of heart sinus venosus, atrium, ventricle and bulbus cordis distinct, three aortic arches appear, dorsal aortae at the level of sinus venosus fuse to form single descending aorta and again separate into two dorsal aortae at the level of 22nd

somite, vitelline arteries arise, two vitelline veins prominent, anterior and posterior cardinal veins join to form common cardinal vein (duct of cuvier).

- (f) **Urinary system** – Mesonephric tubules develop and join pronephric duct, now called mesonephric duct.
- (g) **Coelom** – body coelom not closed.
- (h) **Extra embryonic membranes** – caudal fold of amnion appears, allantoic bud appears from the caudal part of the hindgut.

60-72 hours or 3 days incubated chick embryo:

- (a) **General features** – tail fold appears and thus embryo is demarcated by conical end i.e. tail bud, somite extends down to the tail bud, torsion extends up to 2/3 of the embryo, cervical flexure is so pronounced that the hind brain becomes most anterior of the embryo and fore brain opposes heart, caudal flexure appears and thus tail is curved along the trunk, limb buds appear.
- (b) **Nervous system** – swelling for cerebral hemisphere prominent, diencephalons bears a dorsal evagination for epiphysis cerebri (Pineal body), paired masses of cranial ganglion along the ventro lateral border of myelencephalon appear and they are semilunar ganglia of V, temporarily merged geniculate and acoustic ganglia of VII and VIII, superior (proximal) and petrosal (distal) ganglia of IX, ganglia of X not distinguishable as yet paired cranial nerves III, V, VII and IX appear, spinal ganglia appear as segmented masses along the spinal ganglia.
- (c) **Sense organs** – Eye lens is closed off, otocyst becomes pear shaped closed vesicle.
- (d) **Digestive system** – Pharyngeal membrane ruptures hence stomodium communicates with pharynx, Rathkey's pouch becomes stalked sac, fourth pharyngeal pouch is added, first two closing plates show temporary ruptures, thyroid diverticulum becomes closed pouch, laryngo-tracheal groove appears, foregut presents dilatation of stomach and hence oesophagus and duodenum demarcated, duodenum presents liver and pancreas primordia, mid gut ventrally opens into yolk sac, hind gut gives a ventral diverticulum called allantois.
- (e) **Urinary system** – mesonephric duct approaching hindgut just caudal to allantois cloaca differentiating.
- (f) **Mesentery and coelom** dorsal and ventral mesentery formed, septum transversum appeared and hence pleuro-pericardial and peritoneal cavities formed.
- (g) **Cardiovascular system** – four divisions of heart perfecting, two circuits of blood circulation established.

72-96 hours or 4 days incubated chick embryo:

- 1. **General features (external form)** – Torsion complete and hence embryo lies on the left side, cervical and caudal flexures increasingly pronounced and a new dorsal flexure has appeared and hence embryo becomes C shaped, opening of gut reduced and yolk stalk formed, allantois

demarcated into urinary bladder, branchial arches thicker, limb buds elongate and become paddle like.

- 2. Nervous system** – cerebral hemispheres and mesencephalon distinctly formed, neural tube of hypophysis evaginated and contacts Rathkey's pouch, trochlear (IV CN) from mesencephalon, abducent (VI CN) from metencephalon and vagus (X CN) from myelencephalon appears. Accessory (XI CN) and hypoglossal (XII CN) are just appearing, spinal ganglia are distinct, roots of spinal nerves recognizable, a chain of autonomic dorsal ganglia becomes dorso-lateral to the aorta on each side of the mid brain.
- 3. Sense organs** – eye and ear are not much changed, only eye is enlarged, retina has differentiated into pigmented and sensitive layers, olfactory pits deep.
- 4. Digestive system** – Three or four gill clefts or gill slits may be seen for short period, ventral wall of midgut almost complete, cloacal membrane not ruptured, liver primordia consolidated, dorsal and ventral pancreatic primordia budding from intestine and bile duct.
- 5. Urogenital system** – Pronephric tubules completely disappear mesonephric tubules still developing and differentiating, metanephros or permanent kidney just appearing, ureteric bud is growing out of mesonephric duct near cloaca, secreting tubules of kidney will differentiate from adjacent nephrotome tissue located opposite somites 31-33, mesonephric as a whole bulge in paired longitudinal ridges along each side of the dorsal mesentery, in the narrow strip between mesonephros and mesentery a thickening of peritoneal epithelium gives the first indication of future gonads.
- 6. Cardiovascular system** – External appearances of heart same, internally ventricular wall become thick and spongy and atrial and ventricular portions appear, rudimentary and inconstant 5th aortic arches and 6th (pulmonary) arches are added, first two aortic arches break, dorsal aortae continue as internal carotid arteries, external carotid arteries appear near the ventral ends of the third aortic arches, vitelline veins anastomose behind liver and form portal vein, hepatic, sinusoids have connected with right subcardinal vein which turns into posterior vana cava, in addition to vitelline and intra-embryonic vascular circuits a third one known as allantoic or umbilical circuit is formed, all allantoic (umbilical) arteries ramify in allantoic wall and allantoic (umbilical) veins drain it.
- 7. Extra-embryonic membranes** – Yolk mass almost covered by splanchnopleure, yolk sac wall vascularized, yolk stalk more narrowed, through vitelline vessels the yolk supplies all food materials for the embryonic growth, vascularized yolk sac lies beneath the shell and serves as fetal organ or respiration and excretion, amniotic and chorionic sacs are completely closed and filled with fluid.

7 days old fetus:

1. General features – By the end of this time embryo becomes fetus as it becomes unmistakably bird like in its external features, even though the eye remains disproportionately large, original cervical flexure lost, distinct neck formed, first branchial arches remain as primitive jaw which assume the appearance of beak, first branchial cleft becomes external acoustic meatus and other arches and clefts disappear, forelimb becomes wing like, feather primordia appear, amnion narrows to a tube which contains the allantoic and yolk sac and attaches to the lower body wall as a short umbilical cord.

2. Organs and systems – All organs and systems of the body already formed.

3. Circulatory system – There are two sets of circulation outside the body (a) allantoic and (b) vitelline (omphalomesenteric).

(a) Allantoic circulation – Allantoic blood vessels lie in splanchnic mesoderm of allantoic sac, allantoic (umbilical) arteries show pulsation, left umbilical artery is much larger than right one, they carry impure blood, umbilical veins unite to form single umbilical vein which enters embryo through umbilical opening, it carries oxygenated blood, umbilical arteries lie on both sides of the embryonic disc and umbilical vein on the upper side only.

(b) Vitelline or omphalomesenteric circulation – It consists of vitelline arteries and veins and sinus terminates. These vessels are located in the splanchnic mesoderm of the blastoderm or yolk sac, they assist in transportation of deutoplasm or nutrient from yolk to developing embryo.

14 days old fetus:

General features – Allantois has grown almost entirely around the yolk and the albumen, allantoic blood vessels are in close contact with chorion and shell membrane. Albumen reduced in amount but connected with yolk sac, this connection is called yolk sac umbilicus. Intestine still remains protruded.

21 days old fetus (hatching):

On full time i.e. 21st day chick may be heard producing peeping sound, which indicates that the tip of the beak has penetrated the inner shell membrane of the air sac and that air has entered the lungs. For several days previous to hatching the 'egg tooth' has been developing on the dorsal surface near the end of the beak by which the chick breaks the shell near air sac. Some protruded part of intestine together with reduced yolk sac is withdrawn into the abdominal cavity before hatching. The remaining white albumin is attached to the distal end of the yolk sac and serves as a plug until the body wall closes together. As the intestine contains much yolk the chick needs no extra food for the first 24 hours. Amnion, chorion and allantois are left within the shell. Allantoic arteries and veins are constricted off of the umbilical opening before hatching.

EXERCISE:

1. Draw and labeled the structure of different age groups of chick embryo.

